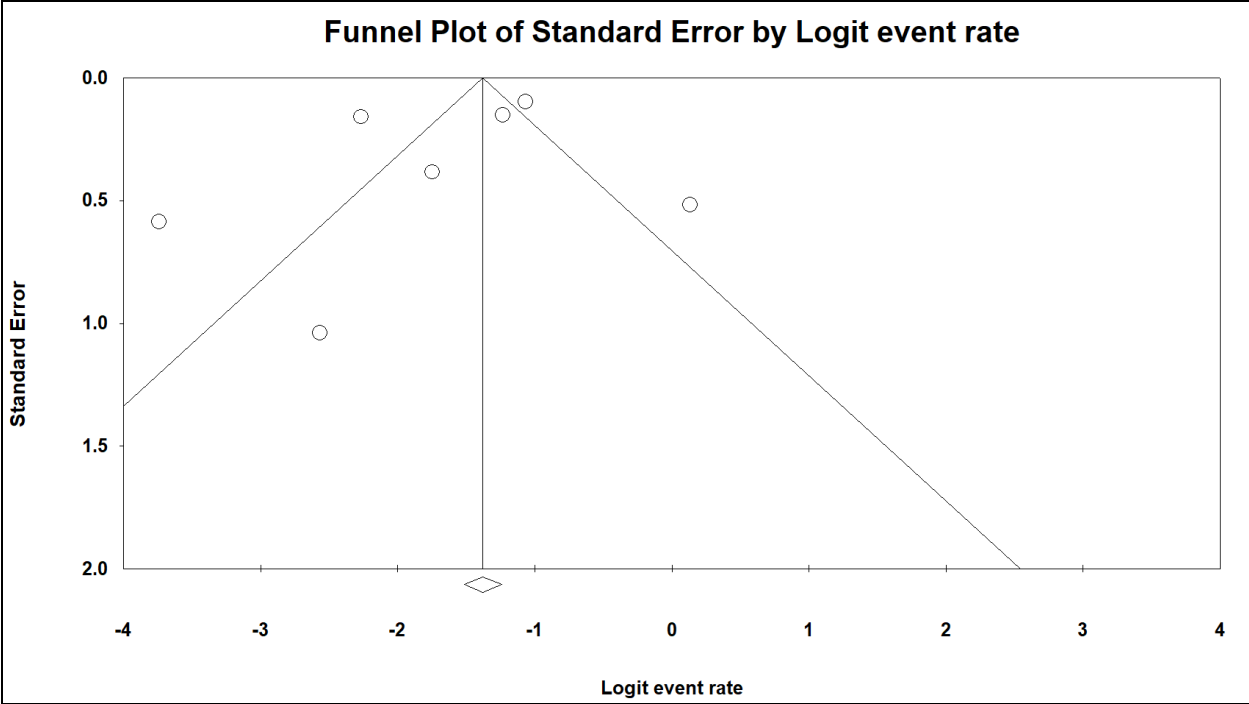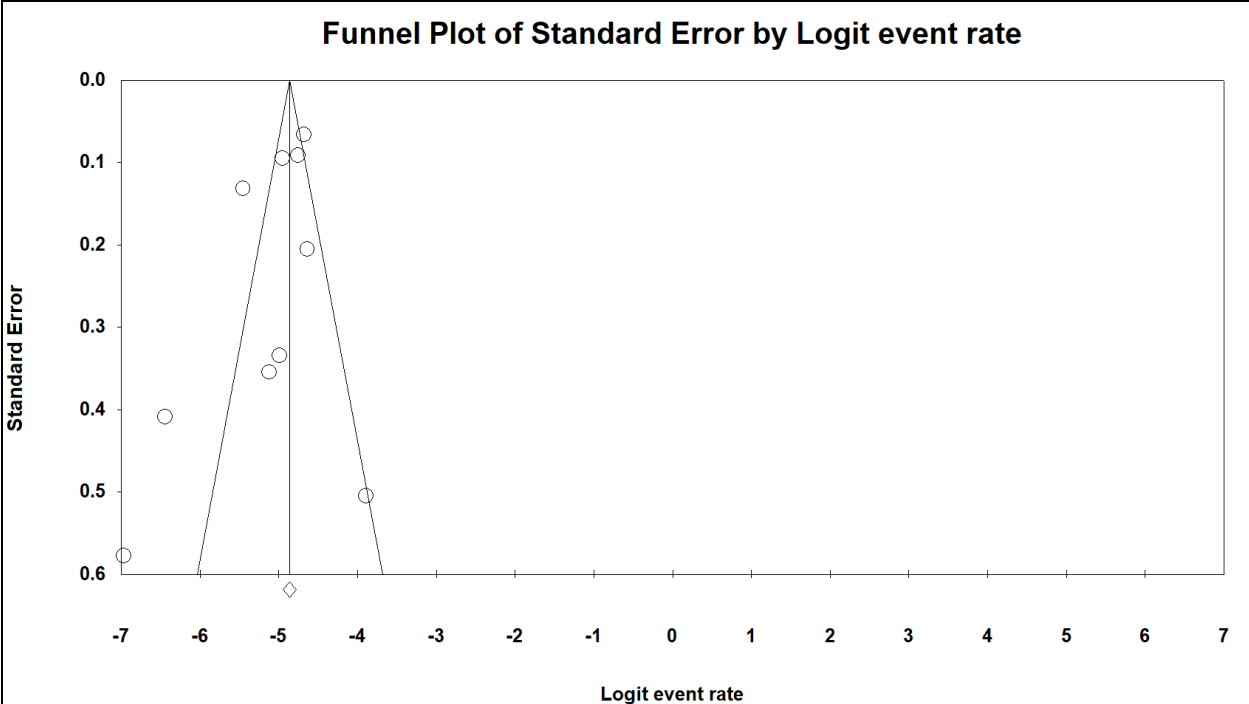
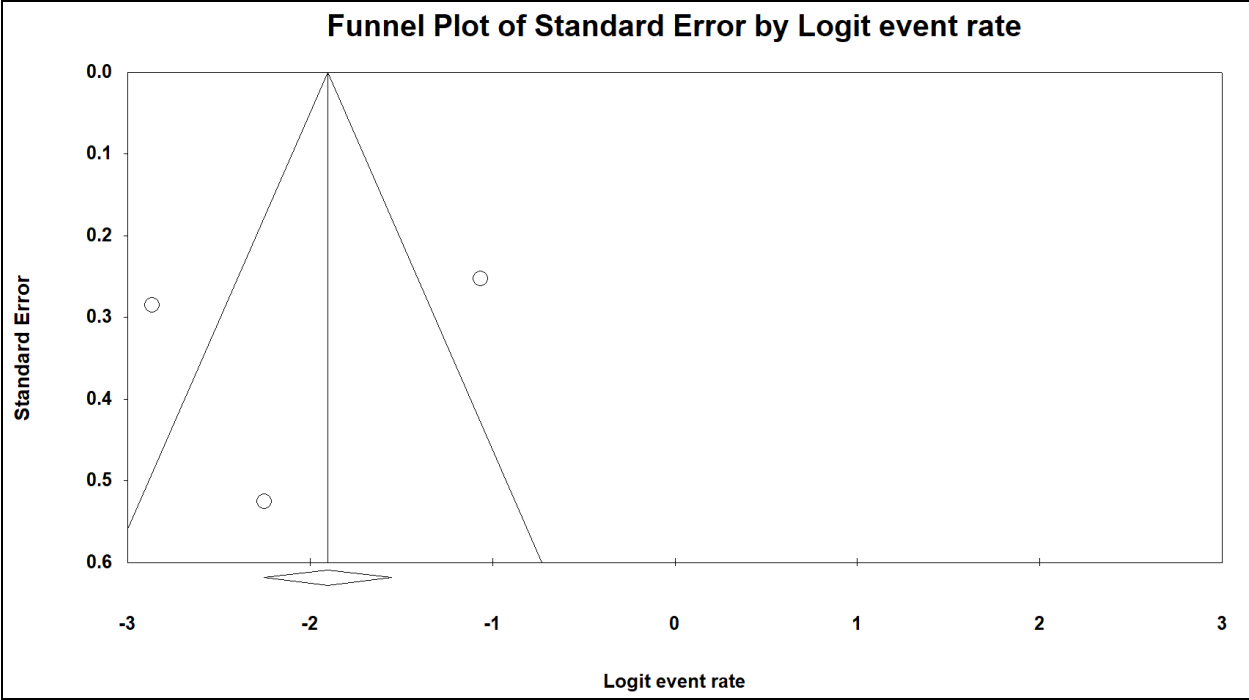


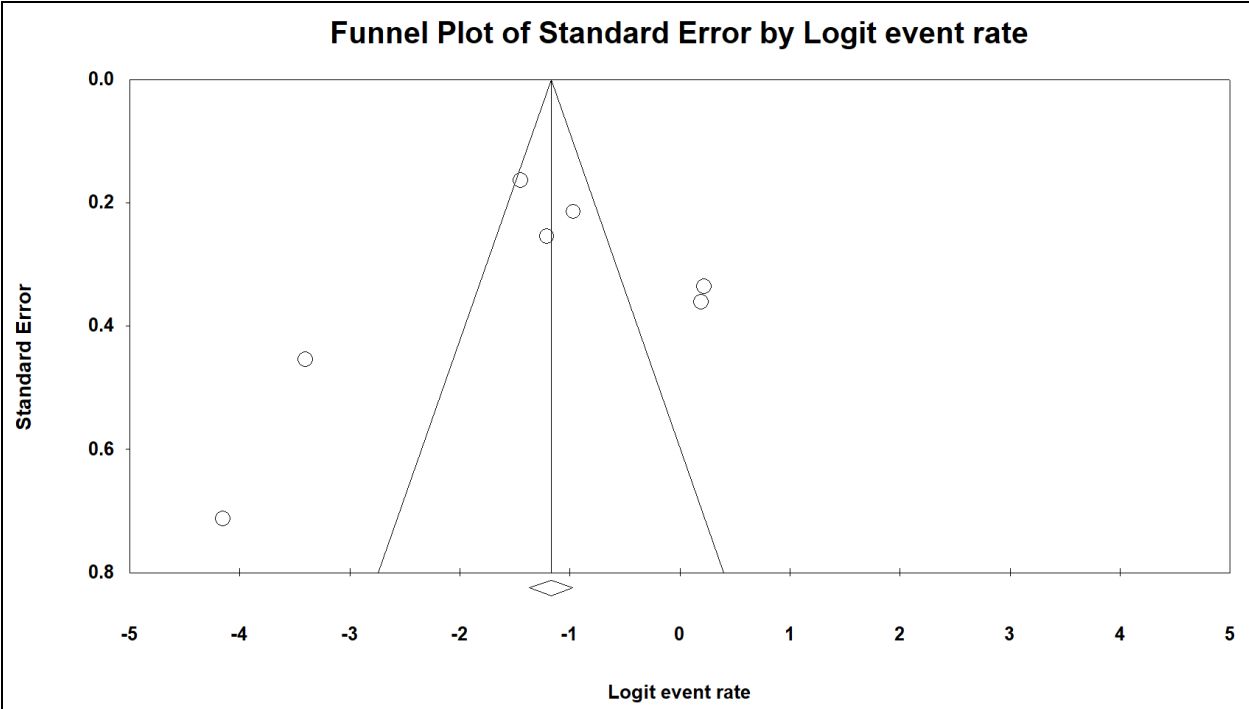
Supplementary Figure S1. Prevalence of pectus excavatum



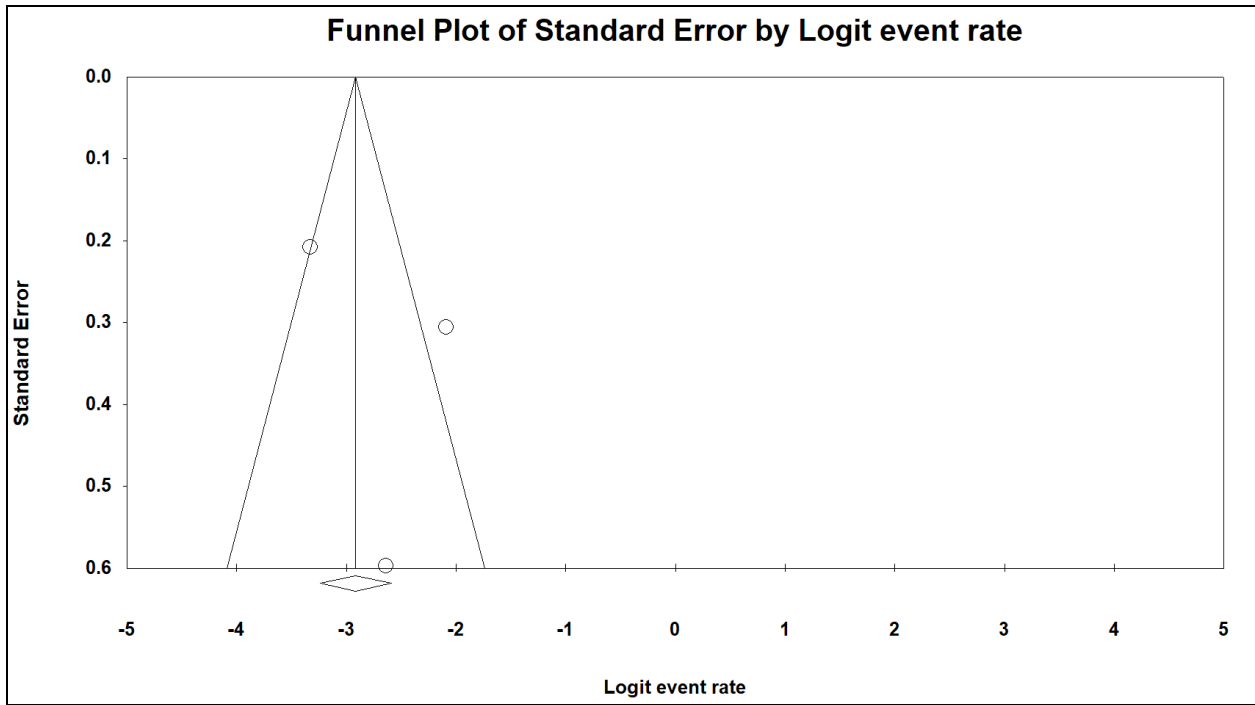
Supplementary Figure S2. Prevalence of pectus carinatum



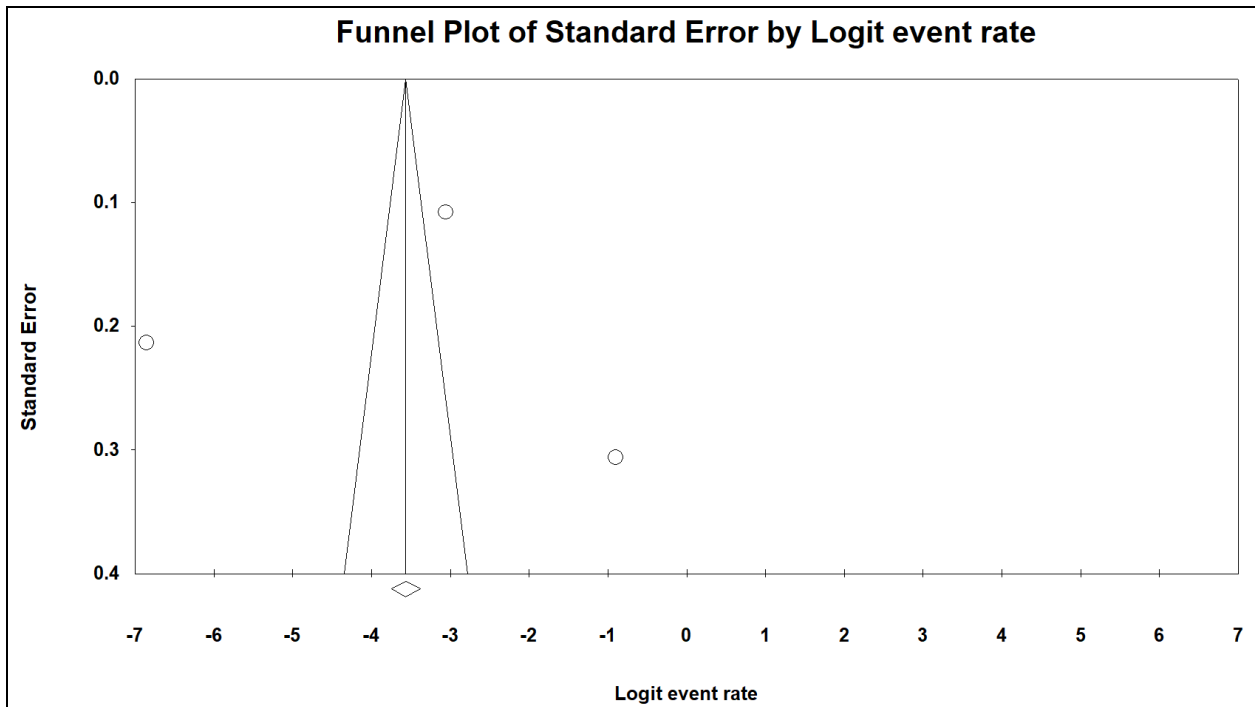
Supplementary Figure S5. Incidence of Marfan's syndrome in pectus deformities



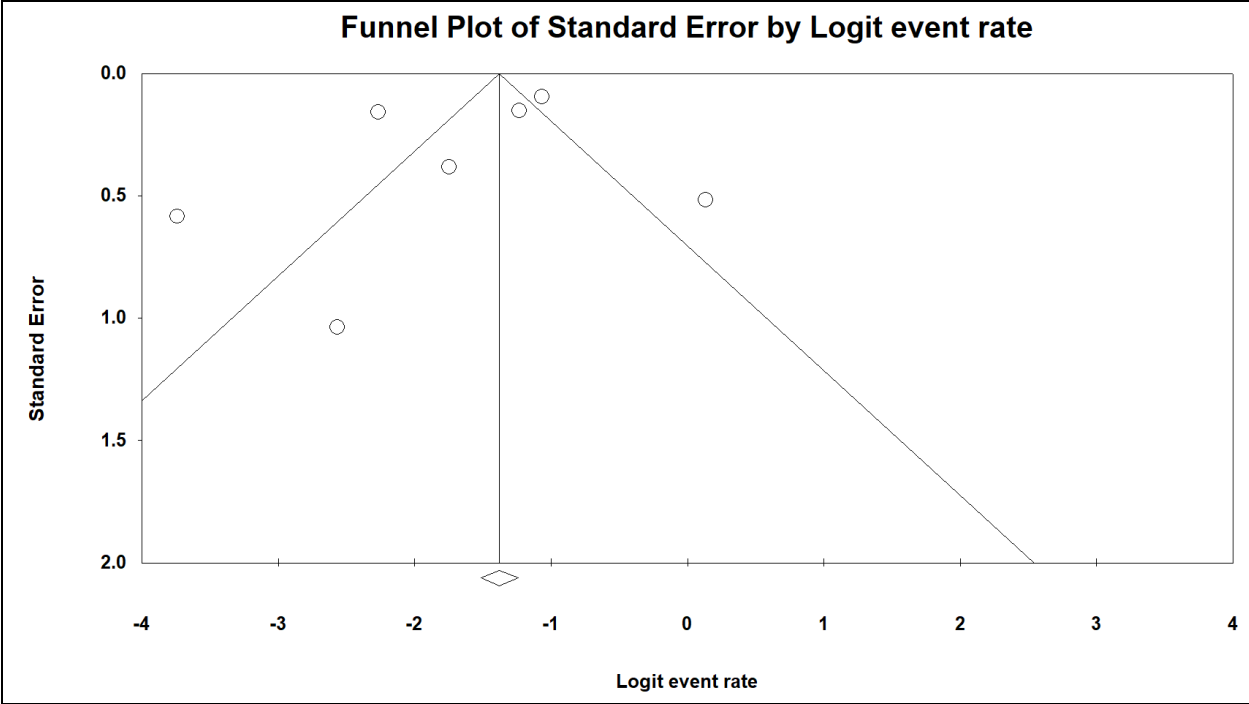
Supplementary Figure S6. Incidence of mitral valve prolapse in pectus deformities



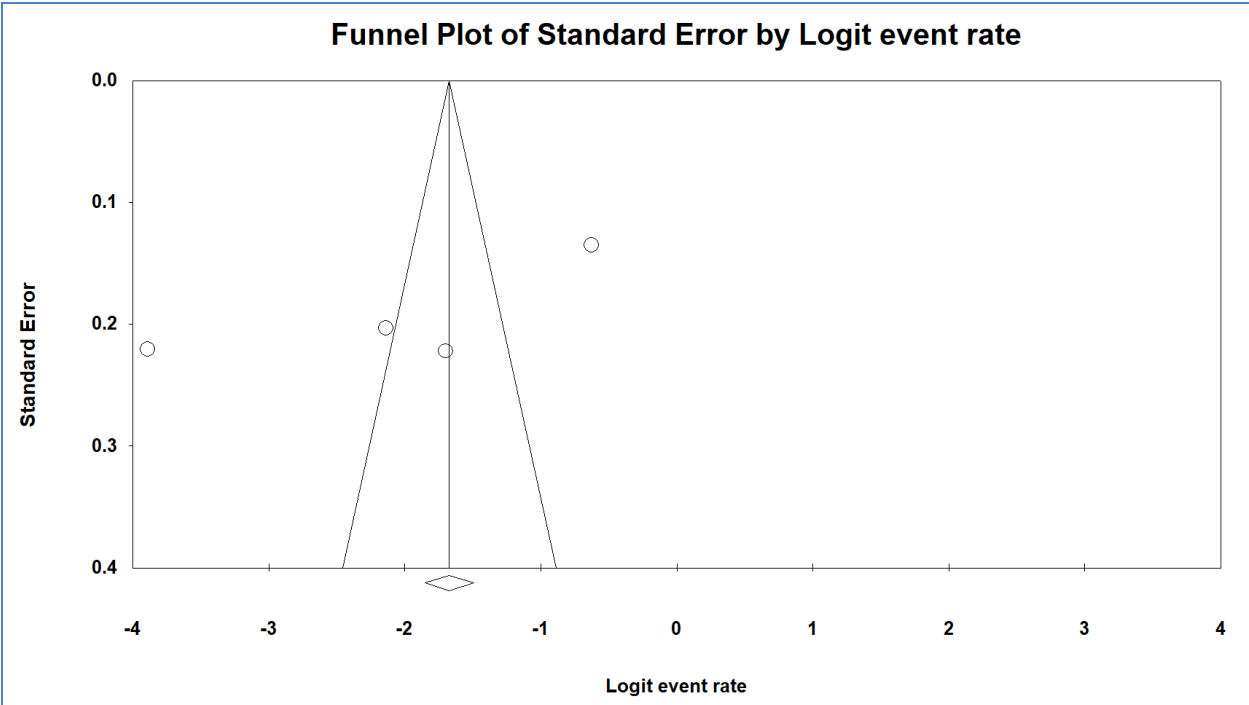
Supplementary Figure S7. Incidence of chest wall deformities in cancers



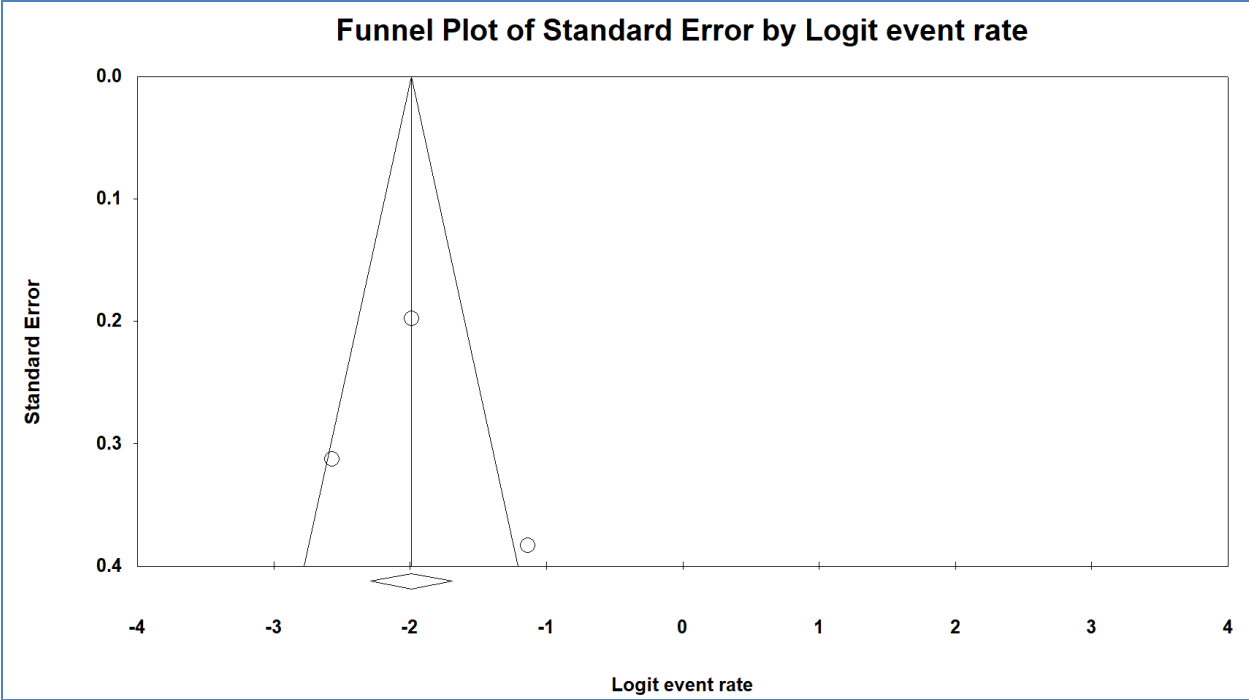
Supplementary Figure S8. Incidence of pectus deformities in congenital heart disease



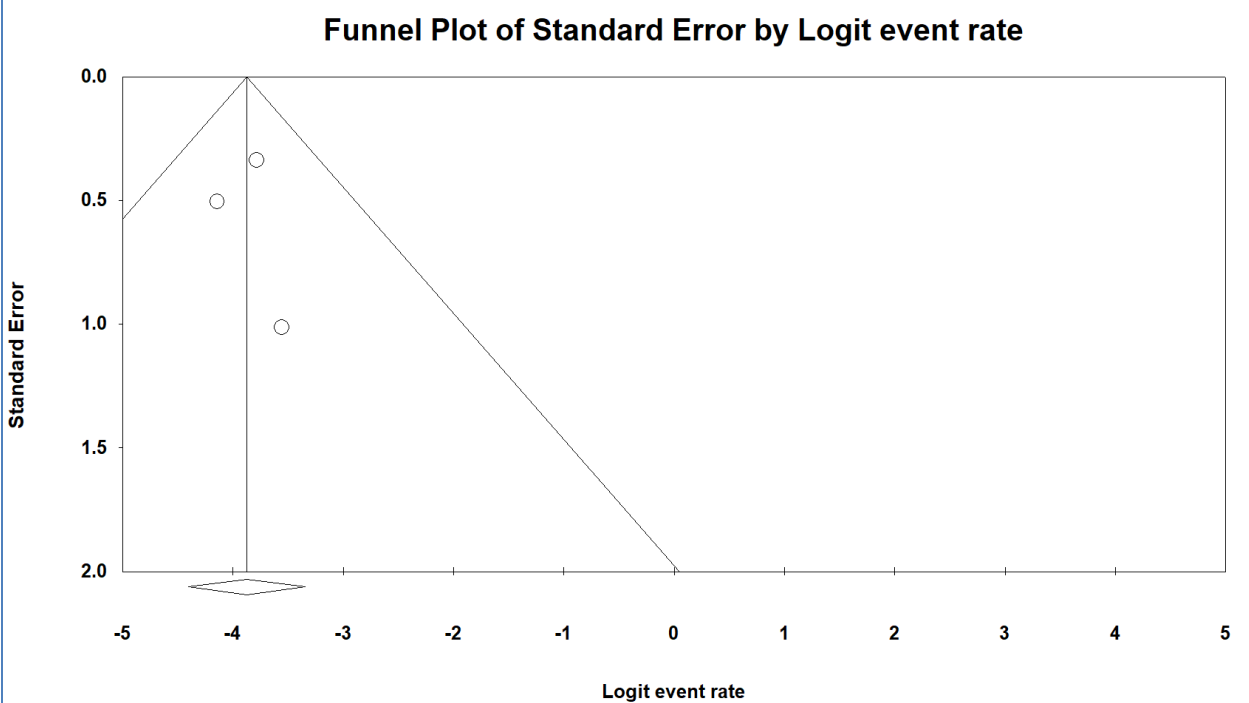
Supplementary Figure S9. Incidence of scoliosis in pectus excavatum



Supplementary Figure S10. Incidence of cardiac anomalies in pectus deformities



Supplementary Figure S11. Incidence of aortic root dilation in pectus deformities



Supplementary Figure S12. Incidence of congenital heart disease in pectus excavatum