

# Use of O-arm with neuronavigation in percutaneous vertebroplasty reduces the surgeon's exposure to intraoperative radiation

Maciej Wojdyn<sup>1</sup>, Olaf Pierzak<sup>1</sup>, Krzysztof Zapałowicz<sup>2</sup>, Maciej Radek<sup>1</sup>

<sup>1</sup>Department of Neurosurgery, Surgery of Spine and Peripheral Nerves, Medical University of Lodz, University Hospital WAM-CSW, Lodz, Poland

<sup>2</sup>Department of Neurosurgery, Prof. Gibiński Central Clinical Hospital, Katowice, Poland

**Submitted:** 20 November 2018

**Accepted:** 7 March 2019

Arch Med Sci 2021; 17 (1): 113–119

DOI: <https://doi.org/10.5114/aoms.2019.84269>

Copyright © 2019 Termedia & Banach

**Corresponding author:**

Maciej Wojdyn MD  
Department  
of Neurosurgery,  
Surgery of Spine  
and Peripheral  
Nerves  
Medical University  
of Lodz  
University Hospital  
WAM-CSW  
113 Żeromskiego St  
90-549 Lodz, Poland  
Phone/fax: +48 42 6333001  
E-mail: mwojdyn@gmail.com

## Abstract

**Introduction:** Percutaneous vertebroplasty is commonly used to treat spinal fractures. The authors compare radiation exposure as potential risk for the surgical team during vertebroplasty guided by O-arm combined with neuronavigation versus vertebroplasty guided by C-arm fluoroscopy.

**Material and methods:** The clinical material consisted of a group of 29 patients (44 vertebrae) with fractures of the thoracolumbar spine treated with percutaneous vertebroplasty guided by O-arm with neuronavigation. In this new method, the operating room staff leaves the operating room for the duration of the 3D scan of the appropriate spine section using the O-arm. In the next stage, the needle of the vertebroplasty system is introduced using only neuronavigation without the need for a radiological view. Finally, the cement injection was made under O-arm fluoroscopic control. The comparison group consisted of a group of 35 patients (40 vertebrae) treated with the classical method using C-arm fluoroscopy. The two methods were compared in terms of the average dose of emitted ionizing radiation through the device (O-arm vs. C-arm) to which surgeons are exposed during percutaneous vertebroplasty.

**Results:** As a result of vertebroplasty procedures guided by neuronavigation, a statistically significant difference between the values of mean dose of radiation emitted by O-arm and C-arm systems was noted. The O-arm emitted 912 cGy/cm<sup>2</sup> vs. 1722 cGy/cm<sup>2</sup> emitted by the C-arm during fluoroscopically assisted procedures and 601.28 cGy/cm<sup>2</sup> vs. 1506.86 cGy/cm<sup>2</sup> per vertebrae.

**Conclusions:** During vertebroplasty with the O-arm combined with neuronavigation the radiation dose is significantly lower as compared with the C-arm used for fluoroscopic guidance, minimizing the potential risk of radiation exposure to surgeons.

**Key words:** vertebral fracture, vertebroplasty, radiation exposure, fluoroscopy, O-arm, neuronavigation.

## Introduction

Spinal surgery is one of the fastest-growing areas of treatment in medicine. In the last two decades, we have observed a large increase in the number of performed spinal procedures, for several reasons: improved imaging diagnostics, introduction of many new techniques and

operational tools, and a significant increase in spine diseases associated with an aging population. For each operation it is necessary to use intraoperative imaging based on ionizing radiation, which greatly facilitates the work of the surgeon, but unfortunately exposes the person to the adverse effects of radiation.

Vertebral compression fractures (VCF) of the thoracolumbar spine have become an important medical and socioeconomic problem. Their etiology is multifactorial: most commonly observed low-energy VCF are sequelae of osteoporosis, while less frequently VCS are caused by trauma or spinal neoplasms. The choice of treatment modality depends on fracture pathogenesis and its morphology and on neurologic symptoms [1]. First described in 1987, percutaneous vertebroplasty (PV) has been ever since widely used to treat VCF without neurologic deficit, vertebral hemangioma or vertebral osteolytic lesions [2]. The PV belongs to the category of the so-called minimally invasive spine surgery (MISS) methods, advocated in last decades in the treatment of VCF (osteoporotic or traumatic) for decreased operative time, less morbidity and simplicity as compared to open surgery [1, 3, 4]. This method involves injection of radiopaque bone cement – most commonly polymethylmethacrylate (PMMA) – into the vertebral body. Conventionally the procedure is performed under fluoroscopic guidance provided by the isocentric C-arm unit [5, 6]. The pedicle access needle is introduced into the vertebral body and is followed by cement injection. Conventional needle placement is focused on anatomic landmarks of vertebrae. However, in certain conditions the visibility of target vertebra may be obstructed due to pathology (high osteoporosis, lytic lesion) and also imaging may be affected by surrounding structures (shoulders, scapulae, ribs and fat tissue).

In recent years, intraoperative spinal navigation techniques coupled with the 3D imaging system (O-arm) have been used to guide precise placement of transpedicular screws, and later to perform percutaneous kyphoplasty [7, 8]. Both mentioned guidance methods with the C-arm or O-arm use radiation posing certain risk for the medical personnel performing the spinal procedures. According to some authors, exposure of the operating room personnel seems to be underestimated [7, 9]. Matityahu *et al.* in a systematic review of exposures during orthopedic procedures highlighted that the highest radiation doses or effective doses were found in spinal surgery, especially for vertebroplasty and kyphoplasty [8].

This study aimed to compare the radiation emitted for vertebroplasty procedures performed using the O-arm combined with neuronavigation and under fluoroscopic guidance using the stan-

dard mobile C-arm. To the best of the authors' knowledge, radiation emitted during C-arm-assisted and O-arm-assisted vertebroplasty has not been compared previously.

## Material and methods

### Population

The subjects of analysis were patients treated at the authors' institution divided into 2 groups. The first group (O-arm group) comprised 29 patients (28 female and 1 male, aged 18–89 years, mean age: 66.7 years) treated from 2016 to 2017 with O-arm-guided vertebroplasty procedures performed in 44 vertebrae.

The reason for compression fractures in the examined group of patients was osteoporosis in 18 (62.06%) patients, pathological fracture in 8 (27.6%) patients and a fresh non-osteoporotic fracture in 3 (10.34%) patients. Fractured vertebrae were situated in the spinal segment from Th1 to L5 and dominated in the thoracolumbar junction. In 40% of cases fractures were multilevel, affecting 2 or 3 vertebrae. The second group (C-arm group) comprised 35 patients with 40 vertebrae treated using fluoroscopic guidance, among whom 26 (74.29%) were female and 9 (25.71%) were male. Patients' age in this group ranged from 30 to 85 years (mean age: 68.9 years). In this group of patients, osteoporosis was also the main cause of spinal fractures (> 70% of patients).

Table I presents patients' demographics and treated vertebrae.

### Surgery

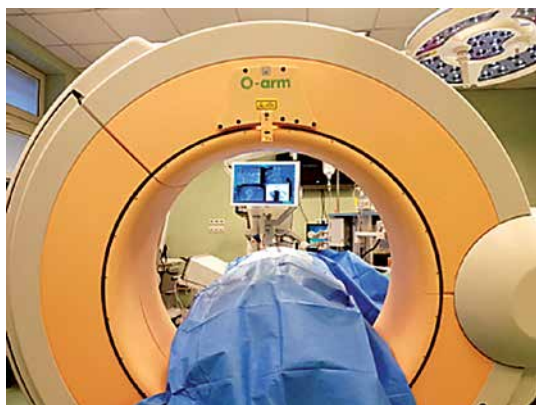Trained operators performed all procedures in an operating room under general anaesthesia.

### O-arm group

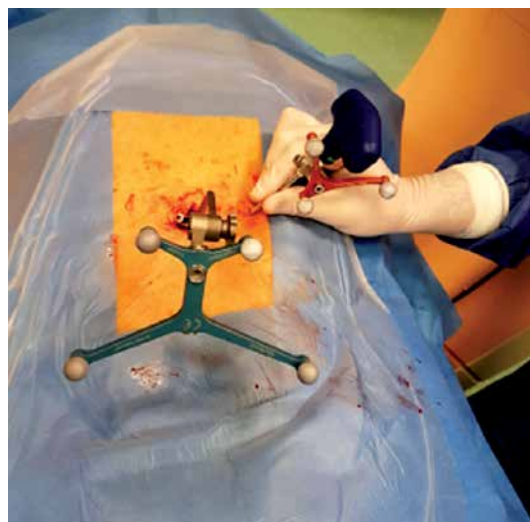
For the O-arm procedure we used the O-arm (Medtronic PLC, Littleton, Massachusetts, USA) integrated with Stealth Station Navigation System (Medtronic PLC, Louisville, Colorado, USA). Patients under general anaesthesia were placed prone on the radiolucent table. Sterile preparation of the operation site was followed by attachment of the reference frame to the spinous process and three-dimensional (3D) examination of the treated spinal segment with the O-arm. During the data acquisition (not exceeding 30 s), all medical personnel were outside the operating theatre. The data were automatically transmitted to the neuronavigation system (Figure 1) and used to guide the vertebroplasty needle into the target vertebra (Figures 2, 3). After proper needle placement the PMMA was injected under the real-time image given by the O-arm switched to the fluoroscopy mode.

**Table I.** Patients' clinical and radiological features

Parameter	O-arm group	C-arm group
Number of patients	29	35
Female	28 (96.55%)	26 (74.29%)
Male	1 (3.45%)	9 (25.71%)
Mean age [years]	66.72 (range: 18–89)	68.91 (range: 30–85)
Vertebrae treated		
Thoracic vertebrae treated	21 (47.72%)	14 (35%)
Lumbar vertebrae treated	23 (52.28%)	26 (65%)
Total number of vertebrae treated	44	40
Treatment details		
Number of vertebrae treated per session:		
Patients with 1 vertebra treated	17 (58.62%)	31 (88.57%)
Patients with 2 vertebrae treated	9 (31.03%)	3 (8.57%)
Patients with 3 vertebrae treated	3 (10.35%)	1 (2.86%)



**Figure 1.** Operating theatre, O-arm (Medtronic PLC, Littleton, Massachusetts, USA) integrated with Stealth Station Navigation System (Medtronic PLC, Louisville, Colorado, USA)



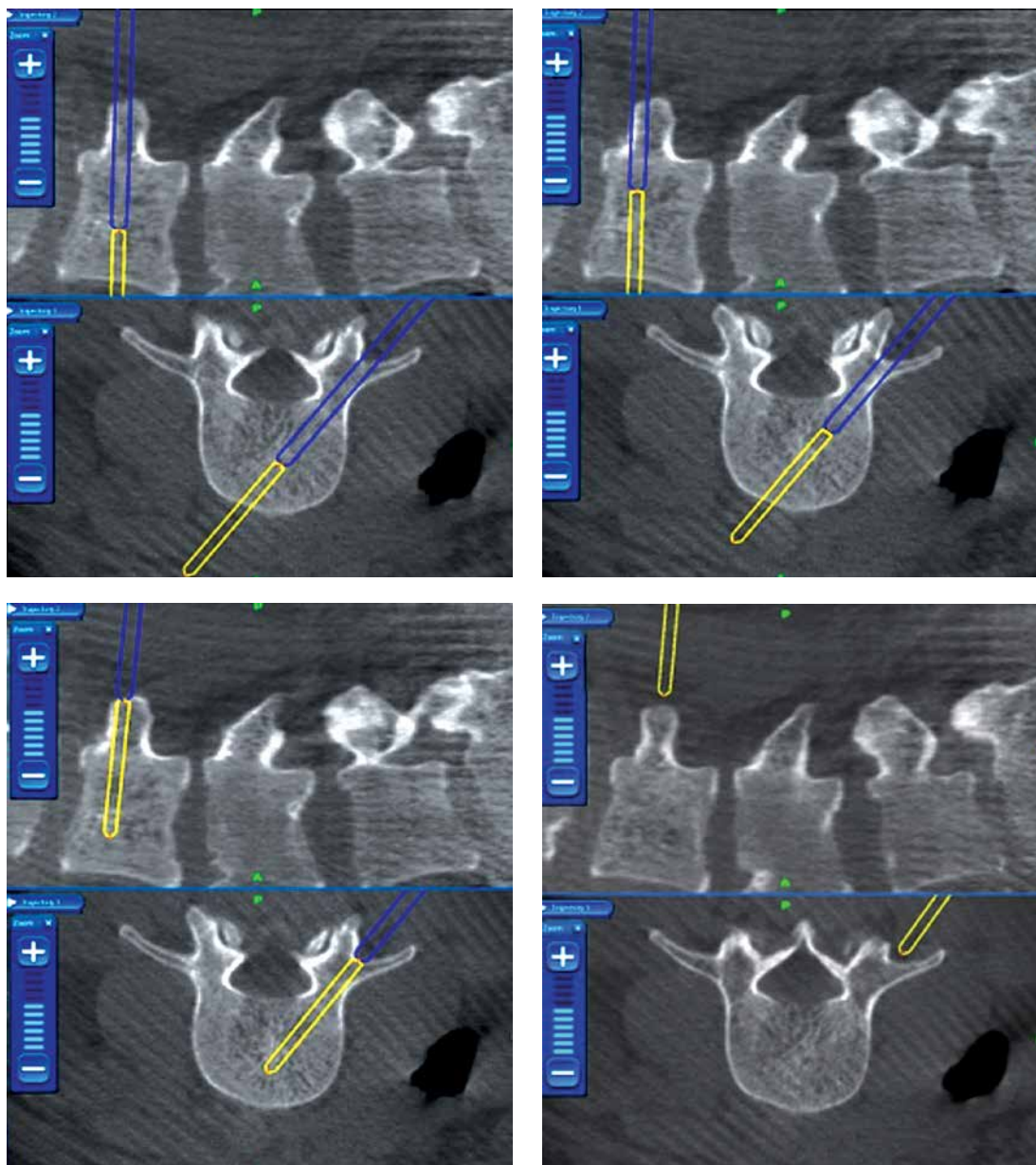
**Figure 2.** Patient under general anaesthesia placed prone on the radiolucent table. Operation site with the reference frame attached to the spinous process via a midline incision. The 3D tracer is attached to the vertebroplasty needle in order to perform continuous neuronavigation

The O-arm also enabled post-procedural 3D imaging to be obtained to estimate the result of vertebral body filling and to visualize potential extravertebral cement leak. Mean volume of PMMA injected per vertebra was 4.03 ml (range: 2.0–7.5 ml). Radiation dose and time were recorded by a built-in dosimeter. In the lumbar vertebrae mean volume of injected PMMA was higher than in the thoracic ones (respectively: 4.58 ml and 3.42 ml).

#### C-arm group

The traditional PV procedure was performed using radio-fluoroscopic guidance with a mobile C-arm fluoroscopy unit (Siremobil Compact L, Siemens, Erlangen, Germany). During the procedure, the X-ray source was primarily placed under a surgical table and could be rotated with the image

intensifier from antero-posterior to lateral position. Exposure parameters were determined by an automatic mode and brightness control. The radiograph unit was equipped with a permanent dose area product meter and a beam-on timer. The radiation time and dose could be read directly from the unit. Patients under general anaesthesia were placed prone on the radiolucent table. The trajectory of the needle and PMMA injection were controlled by the C-arm multiple anteroposterior and lateral images of treated vertebra in pulsed or cine fluoroscopy.



**Figure 3.** Navigation images showing transpedicular advancement of the vertebroplasty needle into the central zone of the target vertebra

### Ethics

All patients provided written consent for treatment. For retrospective study of radiation doses approval of the Institutional Ethics Committee was not necessary.

### Statistical analysis

Sets of radiation dose values without initial and final 3D scans, when the surgeon was outside of the operating room, obtained in the O-arm group were compared with the ones in the C-arm group. We used the data analysis software system Statistica version 9.0 (Stat Soft Inc., 2010) and Microsoft Excel software. Both sets of data were

characterized by minimum, maximum, mean value, median and standard deviation. The following means of testing were used during this study: Student's *t*-test, the Shapiro-Wilk test and the Mann-Whitney *U* test. The level of statistical significance was set at  $p = 0.05$ .

### Results

In the O-arm group, mean radiation dose was 912.29 cGy/cm<sup>2</sup> vs. 1772.13 cGy/cm<sup>2</sup> noted in the C-arm group (Table II). The difference was statistically significant ( $p = 0.000069$ ). In the O-arm group, mean radiation dose per vertebra was 601.28 cGy/cm<sup>2</sup> vs. 1506.86 cGy/cm<sup>2</sup> noted in the C-arm group (Table II). The difference was statisti-



cally significant ( $p = 0.000000004$ ). In neither of the two groups were any surgery-related complications observed.

## Discussion

In recent years, MISS methods have become increasingly popular in treatment of various vertebral compression fractures. Percutaneous techniques such as vertebroplasty, kyphoplasty and transpedicular stabilization are replacing conservative methods of treatment and open surgical methods [1, 3, 4]. Vertebroplasty reinforces the mechanical strength and stabilizes the shape of the fractured vertebral body, which constitute the main advantages of this modality [10]. In consequence, the procedure reduces pain and need of medication and finally improves patients' activity and quality of life.

Recently the World Health Organization has stated that osteoporosis is an emerging health problem in aging societies [11, 12]. In the year 2000, there were about 9 million osteoporotic fractures worldwide with 1.4 million vertebral fractures [13]. In Europe, 400,000 new vertebral fractures are diagnosed yearly and, according to the demographic prognostics, this number may be doubled by the year 2050 [12, 14–16]. Osteoporosis is responsible for 80% of vertebral fractures, while the remaining 20% are a result of trauma and tumors [15, 17]. Increasing use of MISS allows prediction of the growing number of patients treated with these modalities in the future. These techniques as compared with open surgery offer such advantages as smaller wounds, negligible blood loss, shorter hospitalization time, and lower risk of complications [3, 18–20]. However, the risk of radiation for patients and medical staff is the main drawback of MISS procedures, which are generally performed under fluoroscopic guidance [9].

There are many methods of radiological protection that minimize the potential risk of radiation to which surgeons and the rest of the operating

room staff are exposed. To avoid long-term unfavorable effects of ionizing radiation exposure for many years, various radiological shields are used for the most sensitive parts of the human body. The hands of the surgeon, chest, abdomen, neck, thyroid and eyeballs are particularly sensitive when exposed to ionizing radiation.

On the basis of literature analysis, Srinivasan *et al.* proposed recommendations significantly reducing the exposure of spine surgeons and supporting personnel. The authors recommend the use of various types of lead shields, but also the proper setting of parameters and location of the fluoroscope. One of the recommendations to consider is use of the O-arm and neuronavigation in the case of multi-level changes of the spine [21].

In our department, the use of the O-arm with neuronavigation does not exempt the surgeon from observing the basic principles of radiological protection with lead shields protecting sensitive organs, proper setting and distance from the radiation source and leaving the operating room whenever possible.

The above-mentioned rules have to be applied when the O-arm is used in the fluoroscopy mode. During the acquisition of 3D images the operating room staff always leaves the operating room.

Efstathopoulos *et al.* stated that the eye lenses and hands of a surgeon are placed at high risk during vertebroplasty and kyphoplasty [22]. The dose value of ionizing radiation exposure for eye lenses and extremities is limited respectively to 150 mSv and 500 mSv per year [22]. A great deal of attention was paid to staff members who are frequently subject to and are more likely to suffer from radiation side effects than patients rarely exposed to radiation more than once. At present there are no studies comparing fluoroscopically assisted PV and PV guided by O-arm and navigation. The only available research describes differences between fluoroscopically assisted kyphoplasty and O-arm guided kyphoplasty [23, 24]. In

**Table II.** Values of intraoperative radiation exposure

Parameter	Number of patients	Minimum [cGy/cm <sup>2</sup> ]	Maximum [cGy/cm <sup>2</sup> ]	Mean ± SD [cGy/cm <sup>2</sup> ]
Study group (O-arm)	29	290.56	1780	912.29 ±412.72
Control group (C-arm)	35	548.63	3889.61	1722.13 ±884.90
Statistical significance				$p = 0.000069$
Parameter	Number of vertebrae	Minimum [cGy/cm <sup>2</sup> ]	Maximum [cGy/cm <sup>2</sup> ]	Mean ± SD [cGy/cm <sup>2</sup> ]
Study group (O-arm)	44	141.9	1522.32	601.28 ±315.89
Control group (C-arm)	40	548.63	3889.61	1506.86 ±852.00
Statistical significance				$p = 0.000000004$

his prospective study, Schils assessed the average radiation dose and exposure time during percutaneous kyphoplasty guided by O-arm combined with neuronavigation [23]. His study included 54 cases with 76 fractured vertebrae. Among them 70% were a direct result of osteoporosis, 24% were injuries unrelated to osteoporosis and the remaining 6% were pathological fractures caused by multiple myeloma [23].

The authors compared the intraoperative radiation dose during vertebroplasty performed under radio-fluoroscopic guidance (C-arm) versus vertebroplasty guided by O-arm combined with neuronavigation. It is important to note that in the O-arm group the radiation dose levels used for the analysis included only the doses to which the surgeon was exposed during the bone cement implantation (injection), without the initial and final 3D scans, when the personnel always leaves the OR. Thanks to the O-arm combined with navigation, access to the vertebral body is achieved under navigation, without the need of any fluoroscopic control. The present study aimed to determine which method of guidance offers less radiation exposure of patients and medical staff. Similarly to Schils' study [23], this paper presents a comparison of the radiation dose and time of exposure during percutaneous vertebroplasty guided by O-arm combined with neuronavigation. In Schils' study, the average time of fluoroscopy when using the O-arm combined with neuronavigation was 2 min shorter than in cases with use of the C-arm – 3.1 min and 5.1 min respectively [23]. Consequently, less time was needed to carry out the procedure: 38 min for the O-arm and 47 min for the C-arm [23]. Based on these results, Schils states that the O-Arm combined with neuronavigation allows the surgeon to perform kyphoplasty having only 1/3 of radiation typically required for a traditional procedure guided by fluoroscopy [23]. Moreover, Schils *et al.* reported that addition of the Cement Delivery System (CDS) (Medtronic Spine LLC, Sunnyvale, CA, USA) to the O-arm and navigation reduces the dose of radiation by up to 1/5 in comparison to a traditional method [25].

Izadpanah *et al.* measured radiation exposure and operation time in a kyphoplasty procedure with and without a navigation system [24].

Patients were divided into 2 groups: a group of 29 subject to computer navigated kyphoplasty and a control group treated by means of a conventional C-arm controlled kyphoplasty procedure. Results in the latter one revealed that the dose area product (DAP) applied to the patient was on average 1972 cGy cm<sup>2</sup> for the thoracic spine and 2105 cGy cm<sup>2</sup> for the lumbar spine. In the navigated group of patients, DAP was significantly lower: 1318 cGy cm<sup>2</sup> (thoracic spine) and 1245 cGy cm<sup>2</sup> (lumbar spine) [24].

Like in the studies by Schils and Izadpanah *et al.* [24] also our research showed a statistically significant ( $p < 0.05$ ) reduction of radiation exposure of patients and surgeons when applying the O-arm computer navigated procedure. Here DAP applied was on average 912.29 cGy/cm<sup>2</sup> (O-arm group) and 1722.13 cGy/cm<sup>2</sup> (control group) per procedure and 601.28 cGy/cm<sup>2</sup> (O-arm group) vs. 1506.86 cGy/cm<sup>2</sup> (control group) per vertebra.

From a practical point of view PV treatment is technically much more difficult in the treatment of thoracic than lumbar vertebrae. This is due to the anatomy of the thoracic vertebrae: smaller, vertically positioned vertebral pedicles, worse quality of intraoperative X-ray images, especially with C-arm fluoroscopy, and higher possibility of severe neurological deficits due to the risk of thoracic spinal cord damage. These inconveniences usually increase the number of intraoperative fluoroscopy tests performed during the needle insertion into the vertebra. Therefore, we additionally performed a statistical analysis comparing the level of radiation dose between the thoracic and lumbar vertebrae in the O-arm group (lack of statistical significance) and dose of radiation between the thoracic and lumbar vertebrae in the C-arm group (also statistically non-significant). However, when comparing radiation dose levels between the O-arm and C-arm groups, the difference is statistically significant for thoracic vertebrae ( $p = 0.000005$ ) and also for lumbar vertebrae ( $p = 0.00019$ ) (Table III).

From results summarized in Table III another interesting conclusion can be drawn, that the use of the O-arm technique with neuronavigation is particularly useful in the treatment of thoracic vertebrae, which reflects our results – a very low radiation dose (528.14 cGy/cm<sup>2</sup>) and even lower

**Table III.** Values of intraoperative radiation exposure in thoracic and lumbar vertebrae

Parameter	Thoracic vertebrae Mean ± SD [cGy/cm <sup>2</sup> ]	Lumbar vertebrae Mean ± SD [cGy/cm <sup>2</sup> ]	Statistical significance
Study group (O-arm)	528.14 ± 398.98	668.06 ± 201.38	$p = 0.14$
Control group (C-arm)	1667.72 ± 826.03	1420.24 ± 869.09	$p = 0.38$
Statistical significance	$p = 0.000005$	$p = 0.00019$	

than in the case of lumbar vertebrae (668.06 cGy/cm<sup>2</sup>), in contrast to the control group, where the dose was very high in the treatment of thoracic vertebrae (1666.72 cGy/cm<sup>2</sup>) and higher than in the lumbar vertebrae (1420.24 cGy/cm<sup>2</sup>).

In conclusion, percutaneous vertebroplasty guided by O-arm combined with neuronavigation significantly reduces the radiation exposure of surgeons compared to the C-arm fluoroscopy procedure.

### Conflict of interest

The authors declare no conflict of interest.

### References

- Costa F, Ortolina A, Cardia A, et al. Efficacy of treatment with percutaneous vertebroplasty and kyphoplasty for traumatic fracture of thoracolumbar junction. *J Neurosurg Sci* 2009; 53: 13-7.
- Galibert P, Deramond H, Rosat P, Le Gars D. Preliminary note on the treatment of vertebral angioma by percutaneous acrylic vertebroplasty. *Neurochirurgie* 1987; 33: 166-8.
- Rampersaud Raja Y, Annand N, Dekutoski MB. Use of minimally invasive surgical techniques in the management of thoracolumbar trauma. *Spine* 2006; 31: S96-102.
- Weinstein JN, Collalto P, Lehmann TR. Thoracolumbar "burst" fractures treated conservatively: a long-term follow-up. *Spine* 1988; 13: 33-8.
- Baerlocher MO, Saad WE, Dariushnia S, Barr JD, McGraw JK, Nikolic B; Society of Interventional Radiology Standards of Practice Committee. Quality improvement guidelines for percutaneous vertebroplasty. *J Vasc Interv Radiol* 2014; 25: 165-70.
- Jaikumar S, Kim DH, Kam AC. History of minimally invasive spine surgery. *Neurosurgery* 2002; 51 (5 Suppl): S1-14.
- Mahajan A, Samuel S, Saran AK, Mahajan MK, Mam MK. Occupational radiation exposure from C arm fluoroscopy during common orthopaedic surgical procedures and its prevention. *J Clin Diagn Res* 2015; 9: RC01-4.
- Matityahu A, Duffy RK, Goldhahn S, Joeris A, Richter PH, Gebhard Y. The great unknown – a systematic literature review about risk associated with intraoperative imaging during orthopaedic surgeries. *Injury* 2017; 48: 1727-34.
- Boszczyk BM, Bierschneider M, Panzer S, et al. Fluoroscopic radiation exposure of the kyphoplasty patient. *Eur Spine J* 2006; 15: 347-55.
- Guglielmi G, Andreula C, Muto M, Gilula LA. Percutaneous vertebroplasty: indications, contraindications, technique, and complications. *Acta Radiol* 2005; 46: 256-68.
- Misiorowski W. Osteoporoza, osteomalacja, pierwotna nadczynność przytarczyc? Różnicowanie niskiej masy kostnej. *Geratria* 2008; 2: 45-54.
- Pawłowski W, Goniewicz K, Goniewicz M, Lasota D. Fractures in old age: a public health perspective. *Arch Med Sci Aging* 2018; 1: e19-e24.
- Cummings SR, Melton LJ. Epidemiology and outcomes of osteoporotic fractures. *Lancet* 2002; 359: 1761-7.
- Masala S, Lunardi P, Fiori R, et al. Vertebroplasty and kyphoplasty in the treatment of malignant vertebral fractures. *J Chemother* 2004; 16 Suppl 5:30-3.
- Mpotsaris A, Abdolvahabi R, Hoffleith B, et al. Percutaneous vertebroplasty in vertebral compression fractures of benign or malignant origin: a prospective study of 1188 patients with follow-up of 12 months. *Dtsch Arztebl Int* 2011; 108: 331-8.
- Stein KV, Dorner T, Lawrence K, Kunze M, Rieder A. Economic concepts for measuring the costs of illness of osteoporosis: an international comparison. *Wien Med Wochenschr* 2009; 159: 253-61.
- Watts NB, Harris ST, Genant HK. Treatment of painful osteoporotic vertebral fractures with percutaneous vertebroplasty or kyphoplasty. *Osteoporosis Int* 2001; 12: 429-37.
- Korovessis P, Hadjipavlou A, Repantis T. Minimal invasive short posterior instrumentation plus balloon kyphoplasty with calcium phosphate for burst and severe compression lumbar fractures. *Spine* 2008; 33: 658-67.
- Rechtine GR, Bono PL, Cahill D, Bolesta MJ, Chrin AM. Postoperative wound infection after instrumentation of thoracic and lumbar fractures. *J Orthop Trauma* 2001; 15: 566-9.
- Verlaan JJ, Diekerhof CH, Buskens E, et al. Surgical treatment of traumatic fractures of the thoracic and lumbar spine: a systematic review of the literature on techniques, complications, and outcome. *Spine* 2004; 29: 803-14.
- Srinivasan D, Than KD, Wang AC, et al. Radiation safety and spine surgery: systematic review of exposure limits and methods to minimize radiation exposure. *World Neurosurg* 2014; 82: 1337-43.
- Efstathopoulos EP, Pantos I, Andreou M, et al. Occupational radiation doses to the extremities and the eyes in interventional radiology and cardiology procedures. *Br J Radiol* 2011; 84: 70-7.
- Schils F. O-arm-guided balloon kyphoplasty: prospective single-center case series of 54 consecutive patients. *Neurosurgery* 2011; 68 (2 Suppl Operative): ons250-6.
- Izadpanah K, Konrad G, Südkamp NP, Oberst M. Computer navigation in balloon kyphoplasty reduces the intraoperative radiation exposure. *Spine (Phila Pa 1976)* 2009; 34: 1325-9.
- Schils F, Schooijans W, Struelens L. The surgeon's real dose exposure during balloon kyphoplasty procedure and evaluation of the cement delivery system: a prospective study. *Eur Spine J* 2013; 22: 1758-64.