

Medin amyloid and cardiovascular diseases: a review of the biology and the implications for the diagnosis and treatment of cardiac amyloidosis

Yushi Wang¹, Xiaoxing Feng¹, Botao Shen¹, Yujun Du²

¹Department of Cardiology, The First Hospital of Jilin University, Changchun, China

²Department of Nephrology, The First Hospital of Jilin University, Changchun, China

Submitted: 13 August 2020

Accepted: 22 November 2020

Arch Med Sci

DOI: <https://doi.org/10.5114/aoms/130760>

Copyright © 2020 Termedia & Banach

Corresponding author:

Yujun Du

Department of Nephrology

The First Hospital

of Jilin University

71 of Xinmin St

Chaoyang District

Changchun 130021, China

Phone: +86 15843079629

E-mail: duyujun@163.com

Abstract

Medin, a 50-residue cleavage polypeptide of milk fat globule protein epidermal growth factor 8 (MFG-E8), has been deemed to play key roles in the pathogenesis of many cardiovascular diseases, including aortic amyloidosis, hypertension, atherosclerosis, aortic dissection, heart failure, and coronary artery disease. The interactions between medin and vascular cells, such as endothelial cells in intima, vascular smooth muscle cells in media, and fibroblasts in adventitia, are considered to be involved in the pathophysiological processes of the vascular remodelling that underlies cardiovascular diseases. Recent evidence has indicated that medin could also act as a scaffold to facilitate the depositions of other types of amyloid proteins, thereby inducing cardiovascular injuries.

Key words: medin, amyloid, cardiovascular diseases, diagnosis and treatment of cardiac amyloidosis.

Introduction

It is not uncommon for patients with typical angina to present a normal coronary angiography. One pathophysiological explanation for this presentation revolves around amyloid-deposition-related coronary changes. Specifically, an accumulation of amyloid in the coronary artery walls may lead to progressive narrowing of the arterial lumen, thereby causing myocardial ischaemia and cardiac dysfunction [1]. However, few studies have focused on the relationship between medin and coronary artery disease, despite the fact that medin is perhaps the most common amyloid protein that deposits in the aorta [2]. In this review, we summarise the current understandings and mechanisms of the potential role medin plays in cardiovascular diseases, paying particular attention to the potential implications of this role for the diagnosis and treatment of cardiac amyloidosis.

What is medin?

Medin is a 50-residue cleavage polypeptide of milk fat globule protein epidermal growth factor 8 (MFG-E8, Figure 1). Previous studies have confirmed that both MFG-E8 and medin are commonly distributed in the aortic media with “amyloid-like” characteristics [3]. In fact, for virtually

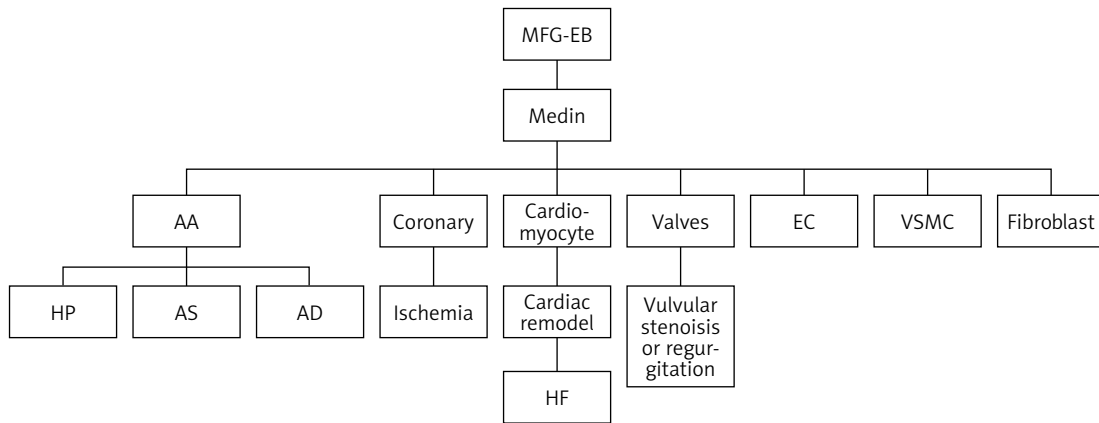


Figure 1. Consequences of Medin distribution in different tissues of the cardiovascular system

AA – aortic amyloidosis, HF – heart failure, AD – aortic dissection, EC – endothelial cell, HP – hypertension, VSMC – vascular smooth muscle cell, AS – atherosclerosis.

every individual over 50 years of age, these amyloid proteins are likely to be found in their aortic walls [4].

The relationship between medin amyloidosis and cardiovascular disease

The cardiovascular deposition of abnormal amyloid fibrils, primarily in the coronary arterial wall, myocardium, and aorta, has been recognised as a key characteristic of cardiac amyloidosis [5]. As a rare disease, cardiac amyloidosis affects 1–5 individuals per 100,000 annually [5]. Meanwhile, the deposition of medin has been confirmed to be the underlying mechanism of age-related vascular stiffness, including in terms of the aorta and other vessels [6], which has also been linked to the pathogenesis of hypertension. The close correlation between medin deposition and hypertension may partly explain the role of medin in the pathogenesis of hypertensive cardiomyopathy and heart failure resulting from increasing cardiac afterload. As noted above, amyloid deposition in intramural coronary arteries may lead to a typical presentation of angina pectoris despite the normal coronary angiography presentation [1]. Indeed, it was demonstrated in a retrospective study that 66% of the 98 studied patients with immunoglobulin light chain (AL) amyloidosis presented intramural amyloid deposits, while 25% had symptoms suggestive of amyloidosis-related ischaemia [7]. Various autopsy studies have also indicated that the infiltration of intramural myocardial vessels by amyloid could, even if no myocardial is involved, cause acute myocardial infarction or even death [8]. This is also reflected by a previous finding that more than 70% of patients with cardiac AL amyloidosis presented myocardial ischaemia without any coronary obstruction during histological analyses [9]. In

addition, cardiac amyloidosis is associated with restrictive cardiomyopathy, with reports indicating that primary AL amyloidosis, familial (ATTR) amyloidosis, and senile systemic amyloidosis invariably involve the myocardium [10]. However, it remains unclear whether medin deposition is involved in the pathogenesis of coronary and cardiac amyloidosis. Larsson *et al.* [11] suggested that medin is likely to facilitate the accumulation of other amyloid proteins, which promotes the formation of amyloidosis. Meanwhile, a previous study demonstrated that medin amyloid could affect the distribution of serum amyloid A (SAA) and thereby promote fibril formation via a cross-seeding dependent mechanism [12]. Interestingly, the co-localisation between medin and AA amyloid has also been observed in the media of the thoracic aorta, while medin amyloid is known to ease the process of protein AA deposition by serving as a scaffold [11]. These results indicate that, despite the uncertainty surrounding the direct deposition of medin in the vascular wall, medin amyloid may at least promote the accumulation of other amyloid fibrillation and the deposition on the vascular wall via scaffolding.

Origins of cardiovascular medin: arterial wall and myocardial cellular sources

The interactions among medin, the cells within the arterial wall, and the myocardium are considered as the main mechanism underlying the role of medin in cardiovascular diseases. The interactions between medin and the vascular cellular components (including the endothelial cells (ECs), vascular smooth muscle cells (VSMCs), and fibroblasts) have been implicated in the pathogenesis of arterial changes in various clinical scenarios, including aging, amyloidosis, hypertension, and atherosclerosis [3]. In addition, as an important

component of the cardiovascular system, cardiomyocytes have also been confirmed as a target of the oxidative stress-related injury induced by medin amyloid [13].

Medin and endothelial cells

Medin causes human microvascular endothelial dysfunction while reducing EC viability, migration, and proliferation. The potential mechanism involves the induction of oxidative and nitrate stress via advanced glycation end-products (AGE), as shown by the fact that the endothelial function can be restored by a high-affinity AGE-specific inhibitor [14, 15]. Moreover, medin may also promote proinflammatory signalling in the ECs, including in terms of interleukin-6 (IL-6) and nuclear factor- κ B (NF- κ B) [14]. Elsewhere, it was demonstrated that overactivated inflammation may be associated with upregulated MFG-E8, the precursor of medin, which could also lead to endothelial dysfunction via mediation of reactive-oxygen-species (ROS)-related mitochondrial DNA damage and the subsequent senescence and apoptosis of the ECs [16, 17]. Other *in-vitro* studies have also demonstrated the direct toxicity of medin to ECs [6].

Medin and the smooth muscle cells

As one of the major cellular components in the aorta media, the phenotype shift of the VSMCs plays a key role in arterial remodelling. It has been demonstrated that chronic exposure of VSMCs to medin is associated with an increased secretion of MMP-2, a marker of VSMC phenotype shifting [18]. In addition, MFG-E8 is found to be abundantly expressed in VSMCs [19–21]. Moreover, it has been demonstrated that during aortic aging, the accumulation of MFG-E8 and medin facilitates a VSMC phenotypic proinflammatory shift [22]. Therefore, medin may be involved in the phenotype shifting process in VSMCs.

Medin and vascular fibroblasts

Fibroblasts, commonly located in the aortic adventitia, are considered to be the last line of defence for the arteries [23]. Accumulating evidence has indicated that adventitial remodelling interacts with the VSMC phenotype shifting process [24–27]. Here, any changes in the adventitia are recognised as a potential sign of vascular disorders [28]. Similarly, AA with medin and MFG-E8 could lead to the activation of fibroblasts, which, in turn, will stimulate the VSMC phenotype change and will contribute to the thickening of the intima and the adventitia [29, 30]. The transition of fibroblasts into myofibroblasts further promotes vascular remodelling.

Medin amyloidosis and hypertension

Vascular amyloidosis caused by the deposition of MFG-E8 and medin is also involved in the pathogenesis and progression of arterial hypertension, which may be mediated by the interaction between MFG-E8 (medin) and the cells within the layers of the arterial wall. For example, the endothelial dysfunction during amyloidosis leads directly to hypertension, with the decrease in nitric oxide resulting in impaired endothelium-dependent vasodilation [31, 32]. The VSMCs also shift their phenotypes during the whole amyloidosis process, which ultimately leads to increased vascular wall stiffening, with decreased elasticity and subsequent hypertension [33]. Moreover, MFG-E8 connects the VSMCs to the elastic fibres of the arteries through binding to tropoelastin via the medin domain in a concentration-dependent manner [34]. Moreover, as previously noted, medin could also influence fibroblast activation in the adventitia, leading to the thickening of both intima and adventitia, and subsequently contributing to hypertension [20]. In addition, the deposition of medin in the vascular extracellular matrix (ECM) may impair the aortic elasticity and cause hypertension. The vascular amyloidosis collectively caused by MFG-E8 and medin accelerates the initiation and progression of hypertension.

Medin amyloidosis and atherosclerosis

First, medin promotes EC senescence and apoptosis, which causes endothelial dysfunction and subsequent atherosclerosis [29, 33]. Moreover, MFG-E8 and medin could also lead to overactivated inflammation, which further contributes to VSMC phenotype shifting and vascular wall remodelling in atherosclerosis [3]. In addition, atherosclerosis is a chronic inflammation accompanied by an increased expression of the acute phase isoforms of SAA. Meanwhile, SAA has many putative functions that are relevant to atherogenesis, including facilitating the migration of blood cells into lesions, reducing the anti-inflammatory ability of high-density lipoprotein (HDL), and influencing lipoprotein retention in the vascular wall [35, 36].

Medin, amyloidosis, and aneurysm dissection

Aneurysm dissection, which often occurs along with the development of atherosclerosis and hypertension, is known to be closely associated with amyloidosis. Medin is primarily located in the internal elastic lamina of the aorta, which may cause a weakening of the aortic aneurysm wall by affecting the elasticity of the intima [6]. Moreover, medin is significantly upregulated in the aorta of patients with thoracic aortic aneurysm and dissec-

tion when compared with those with a normal aorta [37]. In addition, because medin contributes to VSMC phenotype shifting, the secretion of MMP-2 is subsequently increased, which may also induce aneurysm dissection via the degradation of the elastin and collagen of the vascular wall [18].

Medin, amyloidosis, valvular diseases, and cardiomyopathy

Patients with cardiac amyloidosis generally have poor prognosis, especially those with AL, with a median survival of less than a year. Here, heart failure is always the final stage of cardiac amyloidosis [5]. The current understandings of the mechanisms linking medin with heart failure mainly include the following. First, medin assists in the accumulation of other amyloid proteins to promote the formation of amyloidosis [11], which indicates that medin can be regarded as the promoter of the heart failure caused by cardiac amyloidosis. Second, with the development of the medin-induced aortic amyloidosis, the blood pressure gradually rises, leading to heart failure by increasing cardiac afterload [6]. Third, as was noted above, due to the depositions of any type of amyloid proteins in the coronary artery aggravated by medin, myocardial ischaemia or even infarction may also lead to heart failure [8]. Furthermore, the valves within the heart are also the targets of the deposition of amyloid proteins. For certain, the stenosis or regurgitation of amyloidosis valves is also likely to lead to heart failure. MFG-E8, as an essential component of the ECM, is enriched in valves and is highly relevant to valve biology and functioning. The MFG-E8 expression in the ECM that lies within the hinge region of the aortic valve localised to the aortic side is associated with valve degeneracy and calcification, which ultimately leads to the need for valve transplantation if refractory heart failure is to be prevented [38]. Taken as a whole, regardless of where the amyloid proteins may deposit, biventricular systolic dysfunction may ultimately develop in the patients [10].

Current diagnosis and treatment

Diagnosis of cardiac amyloidosis

Several methods are currently available for the diagnosis of cardiac amyloidosis. Among them, echocardiography is recommended as a routine examination for patients with suspected amyloidosis, in terms of evaluating the possible involvement in the structure of the heart [5], although this generally lacks specificity. Meanwhile, cardiac magnetic resonance imaging should be performed because any amyloid fibril deposition in the interstitium may manifest itself as a reservoir for gad-

olinium accumulation characterised by late gadolinium enhancement [39], which is of diagnostic significance for cardiac amyloidosis. Finally, as the gold standard for cardiac amyloidosis diagnosis, endomyocardial biopsy is suggested in many cases where the condition is highly suspected. However, this examination is invasive, and it has been suggested that fine-needle aspiration of the abdominal fat may be an alternative approach [5].

Diagnosis of coronary artery amyloidosis

The clinical diagnosis of coronary artery amyloidosis is challenging [40]. Here, it has been suggested that the impairment in coronary flow velocity reserve (CFVR) may be a characteristic feature of coronary artery amyloidosis because the disease is likely to affect microvascular functioning [41]. The measurement of this impairment not only plays a diagnostic role but could also be used to monitor the efficacy of the patients' therapy.

Treatment

Myeloma-based chemotherapy or stem cell transplantation are the currently available therapies used to combat the light-chain-producing plasma cells in cardiac amyloidosis. However, in patients with a severe cardiac condition, these therapies may not be tolerated. Unfortunately, no treatment that targets amyloid fibril accumulation is currently available. More treatments are thus clearly needed.

Specific treatment

Several strategies were proposed by Clemmensen *et al.* [40] in relation to vascular wall amyloidosis, including the prevention of amyloidosis accumulation through chemotherapy, and various methods for improving myocardial perfusion. Meanwhile, it is anticipated that treatments targeting medin will help impede the development of hypertension and atherosclerosis and could even inhibit the deposition of other amyloid proteins.

Summary

Medin is not only a key factor in vascular amyloidosis but also in all types of severe vascular diseases, including hypertension, atherosclerosis, and aortic dissection. Furthermore, by acting as a scaffold, medin may facilitate the depositions of other types of amyloid protein, including the ones in cardiomyocytes and at the wall of coronary arteries. In terms of the cellular mechanism, medin closely interacts with the intima ECs, the media VSMCs, and the adventitia fibroblasts, all of which are related to vascular remodelling. Therefore, the functioning and the remodelling of the

large arteries and the small vessels could be affected by medin. It is reasonable to presume that medin amyloidosis is involved in the pathogenesis of hypertension, atherosclerosis, aortic dissection, and heart failure. Nonetheless, the means of amyloidosis diagnosis and treatment remain limited, and there is an urgent need to address these limitations in terms of developing novel treatment modalities that target the deposition of medin in the cardiovascular system.

Ethical approval and consent to participate

I confirm that I have read the Editorial Policy pages. This study was conducted with approval from the Ethics Committee of The First Hospital of Jilin University. This study was conducted in accordance with the declaration of Helsinki. Written informed consent was obtained from all participants.

Acknowledgments

We would like to acknowledge the hard and dedicated work of all the staff that implemented the intervention and evaluation components of the study.

Conflict of interest

The authors declare no conflict of interest.

References

1. George A, McClements B. Cardiac amyloidosis presenting as recurrent acute coronary syndrome with unobstructed coronary arteries: case report. *Indian Heart J* 2015; 67: 570-3.
2. Davies HA, Madine J, Middleton DA. Comparisons with amyloid-beta reveal an aspartate residue that stabilizes fibrils of the aortic amyloid peptide medin. *J Biol Chem* 2015; 290: 7791-803.
3. Wang Y, Feng X, Shen B, Ma J, Zhao W. Is vascular amyloidosis intertwined with arterial aging, hypertension and atherosclerosis? *Front Genet* 2017; 8: 126.
4. Mucchiano G, Cornwell GG 3rd, Westermark P. Senile aortic amyloid. Evidence for two distinct forms of localized deposits. *Am J Pathol* 1992; 140: 871-7.
5. Falk RH. Diagnosis and management of the cardiac amyloidoses. *Circulation* 2005; 112: 2047-60.
6. Madine J, Middleton DA. Comparison of aggregation enhancement and inhibition as strategies for reducing the cytotoxicity of the aortic amyloid polypeptide medin. *Eur Biophys J* 2010; 39: 1281-8.
7. Mueller PS, Edwards WD, Gertz MA. Symptomatic ischemic heart disease resulting from obstructive intramural coronary amyloidosis. *Am J Med* 2000; 109: 181-8.
8. Morin J, Schreiber WE, Lee C. Sudden death due to undiagnosed primary amyloidosis. *J Forensic Sci* 2013; 58 Suppl 1: S250-2.
9. Migrino RQ, Truran S, Gutterman DD, et al. Human microvascular dysfunction and apoptotic injury induced by AL amyloidosis light chain proteins. *Am J Physiol Heart Circ Physiol* 2011; 301: H2305-12.
10. Bhogal S, Ladia V, Sitwala P, et al. Cardiac amyloidosis: an updated review with emphasis on diagnosis and future directions. *Curr Probl Cardiol* 2018; 43: 10-34.
11. Larsson A, Malmstrom S, Westermark P. Signs of cross-seeding: aortic medin amyloid as a trigger for protein AA deposition. *Amyloid* 2011; 18: 229-34.
12. Davies HA, Lee CF, Miller L, Liu LN, Madine J. Insights into the origin of distinct medin fibril morphologies induced by incubation conditions and seeding. *Int J Mol Sci* 2018; 19: 1357.
13. Davies HA, Phelan MM, Wilkinson MC, et al. Oxidative stress alters the morphology and toxicity of aortic medial amyloid. *Biophys J* 2015; 109: 2363-70.
14. Migrino RQ, Davies HA, Truran S, et al. Amyloidogenic medin induces endothelial dysfunction and vascular inflammation through the receptor for advanced glycation endproducts. *Cardiovasc Res* 2017; 113: 1389-402.
15. Saki G, Eidi A, Mortazavi P, Panahi N, Vahdati A. Effect of beta-asarone in normal and beta-amyloid-induced Alzheimeric rats. *Arch Med Sci* 2020; 16: 699-706.
16. Wang M, Zhang J, Jiang LQ, et al. Proinflammatory profile within the grossly normal aged human aortic wall. *Hypertension* 2007; 50: 219-27.
17. Wang M, Zhang J, Spinetti G, et al. Angiotensin II activates matrix metalloproteinase type II and mimics age-associated carotid arterial remodeling in young rats. *Am J Pathol* 2005; 167: 1429-42.
18. Peng S, Larsson A, Wassberg E, et al. Role of aggregated medin in the pathogenesis of thoracic aortic aneurysm and dissection. *Lab Invest* 2007; 87: 1195-205.
19. Haggqvist B, Naslund J, Sletten K, et al. Medin: an integral fragment of aortic smooth muscle cell-produced lactadherin forms the most common human amyloid. *Proc Natl Acad Sci USA* 1999; 96: 8669-74.
20. Peng S, Westermark GT, Naslund J, Haggqvist B, Glennert J, Westermark P. Medin and medin-amyloid in ageing inflamed and non-inflamed temporal arteries. *J Pathol* 2002; 196: 91-6.
21. Peng S, Glennert J, Westermark P. Medin-amyloid: a recently characterized age-associated arterial amyloid form affects mainly arteries in the upper part of the body. *Amyloid* 2005; 12: 96-102.
22. Wang M, Jiang L, Monticone RE, Lakatta EG. Proinflammation: the key to arterial aging. *Trends Endocrinol Metab* 2014; 25: 72-9.
23. Michel JB, Thauinat O, Houard X, Meilhac O, Caligiuri G, Nicoletti A. Topological determinants and consequences of adventitial responses to arterial wall injury. *Arterioscler Thromb Vasc Biol* 2007; 27: 1259-68.
24. Grabner R, Lotzer K, Dopping S, et al. Lymphotoxin beta receptor signaling promotes tertiary lymphoid organogenesis in the aorta adventitia of aged ApoE^{-/-} mice. *J Exp Med* 2009; 206: 233-48.
25. Moos MP, John N, Grabner R, et al. The lamina adventitia is the major site of immune cell accumulation in standard chow-fed apolipoprotein E-deficient mice. *Arterioscler Thromb Vasc Biol* 2005; 25: 2386-91.
26. Passman JN, Dong XR, Wu SP, et al. A sonic hedgehog signaling domain in the arterial adventitia supports resident Sca1⁺ smooth muscle progenitor cells. *Proc Natl Acad Sci USA* 2008; 105: 9349-54.
27. Sierevogel MJ, Velema E, van der Meer FJ, et al. Matrix metalloproteinase inhibition reduces adventitial thickening and collagen accumulation following balloon dilation. *Cardiovasc Res* 2002; 55: 864-9.
28. Wang M, Khazan B, Lakatta EG. Central arterial aging and angiotensin II signaling. *Curr Hypertens Rev* 2010; 6: 266-81.

29. Najjar SS, Scuteri A, Lakatta EG. Arterial aging: is it an immutable cardiovascular risk factor? *Hypertension* 2005; 46: 454-62.
30. Sepulveda C, Palomo I, Fuentes E. Mechanisms of endothelial dysfunction during aging: predisposition to thrombosis. *Mech Ageing Dev* 2017; 164: 91-9.
31. Puddu P, Puddu GM, Zaca F, Muscari A. Endothelial dysfunction in hypertension. *Acta Cardiol* 2000; 55: 221-32.
32. Shi X, Zhang K, Wang P, et al. Association of masked uncontrolled hypertension and cardiovascular diseases in treated hypertensive patients. *Arch Med Sci* 2019; 16: 538-44.
33. Wang M, Monticone RE, Lakatta EG. Proinflammation of aging central arteries: a mini-review. *Gerontology* 2014; 60: 519-29.
34. Larsson A, Peng S, Persson H, et al. Lactadherin binds to elastin: a starting point for medin amyloid formation? *Amyloid* 2006; 13: 78-85.
35. Getz GS, Krishack PA, Reardon CA. Serum amyloid A and atherosclerosis. *Curr Opin Lipidol* 2016; 27: 531-5.
36. González FEM, Ponce-Ruiz N, Rojas-García AE, et al. PON1 concentration and high-density lipoprotein characteristics as cardiovascular biomarkers. *Arch Med Sci Atheroscler Dis* 2019; 4: e47-54.
37. Larsson A, Soderberg L, Westermark GT, et al. Unwinding fibril formation of medin, the peptide of the most common form of human amyloid. *Biochem Biophys Res Commun* 2007; 361: 822-8.
38. Angel PM, Nusinow D, Brown CB, et al. Networked-based characterization of extracellular matrix proteins from adult mouse pulmonary and aortic valves. *J Proteome Res* 2011; 10: 812-23.
39. White JA, Fine NM. Recent advances in cardiovascular imaging relevant to the management of patients with suspected cardiac amyloidosis. *Curr Cardiol Rep* 2016; 18: 77.
40. Clemmensen TS, Molgaard H, Andersen NF, Baerentzen S, Soerensen J, Poulsen SH. A rare presentation of cardiac amyloid deposits isolated to intramural vessels. *Echocardiography* 2016; 33: 1777-80.
41. Quarta CC, Solomon SD, Uraizee I, et al. Left ventricular structure and function in transthyretin-related versus light-chain cardiac amyloidosis. *Circulation* 2014; 129: 1840-9.