Clinical research

Orthopedics and Traumatology

# Changes in quality of life of patients with Blount's disease undergoing simultaneous bilateral varus deformity correction using the Ilizarov method

Łukasz Szelerski[1]*, Sławomir Żarek[1], Radosław Górski[1], Karol Mochocki[1], Ryszard Górski[1], Andżelika Pajchert-Kozłowska[2], Paweł Małdyk[1], Piotr Morasiewicz[2,3,4]

[1]Department of Orthopedics and Musculoskeletal Traumatology, Medical University of Warsaw, Poland
[2]Department and Clinic of Orthopaedic and Traumatologic Surgery, Wroclaw Medical University, Wroclaw, Poland
[3]Department of Orthopaedic and Trauma Surgery, University Hospital in Opole, Poland
[4]Institute of Medical Sciences, University of Opole, Poland

**Submitted:** 2 January 2021; **Accepted:** 20 April 2021
**Online publication:** 23 April 2021

Arch Med Sci 2026; 22 (5): 2852–2859
DOI: https://doi.org/10.5114/aoms/135942
Copyright © 2021 Termedia & Banach

***Corresponding author:**
Łukasz Szelerski
Department of Orthopedics and Musculoskeletal Traumatology
Medical University of Warsaw
Lindeya 4
02-005 Warsaw, Poland
Phone: +48 796850304
E-mail: Lszelerski@gmail.com

## Abstract

**Introduction:** Blount's disease is a growth disorder of the proximal tibia, which leads to varus deformity and internal rotation of the tibia. The treatment is mainly surgical and involves proximal tibial osteotomy and deformity correction. The aim of this study was to assess changes in quality of life in patients with tibia vara deformity who underwent correction via the Ilizarov method.

**Material and methods:** A total of 23 patients with Blount's disease who had undergone bilateral varus deformity correction with the Ilizarov method were included in this study. The following parameters were assessed retrospectively: duration of treatment with Ilizarov frames, baseline and postoperative values of the medial proximal tibial angle (MPTA) and mechanical axis deviation (MAD). The quality of life was assessed with the Short Form (SF)-36 questionnaire.

**Results:** The study population comprised 13 females and 10 males (mean age: 28.43 years), in whom the Ilizarov fixators were maintained for an average of 106.65 days. MAD values diminished significantly after the surgery. We also observed significant increases in the MPTA values. The SF-36 scores increased across all domains, which indicates a significant improvement in the postoperative quality of life.

**Conclusions:** Simultaneous bilateral correction of the varus deformity with Ilizarov external fixators is a potentially safe and effective treatment method. It may help reduce pain and improve gait, thereby improving quality of life. The duration of treatment depends to a large extent on patient's cooperation, attitude, and self-discipline.

**Key words:** Ilizarov method, genu varum, Blount disease, external fixator, limb deformity.

## Introduction

Blount's disease is a growth disorder affecting the proximal tibia, which leads to varus deformity and internal tibial rotation [1] (Figure 1). In 1937, Blount distinguished two clinical variants of this deformity, not-



Creative Commons licenses: This is an Open Access article distributed under the terms of the Creative Commons Attribution-NonCommercial-ShareAlike 4.0 International (CC BY -NC -SA 4.0). License (http://creativecommons.org/licenses/by-nc-sa/4.0/).

ing their different age of onset. The infantile, or early-onset, form typically develops during the first 3 years of life and is usually bilateral. The adolescent, or late-onset, form develops at the age of 11 years or later [2, 3].

Although the etiology of Blount's disease is unknown, there has been research into possible associations with obesity and vitamin $D_3$ deficiency [3, 4]. Left untreated, Blount's disease leads to progressive limb deformity, with the associated mechanical overload of the medial knee compartment and the consequent development of knee osteoarthritis [3, 5].

Conservative management has been unsuccessful. The surgical approaches currently used for varus deformity correction are tibial hemiepiphysiodesis (in patients whose growth plates have not yet fused) and corrective osteotomy [3, 6]. Deformity correction may be achieved either intraoperatively using osteotomy and metal implants or gradually, for example with an Ilizarov fixator [7–9]. One particularly common technique is proximal tibial osteotomy. Restoring the normal mechanical axis of the limb reduces the medial overload exerted on the proximal tibia and contributes towards relieving pain and improving gait [10, 11].

There have been literature reports describing various surgical techniques and successful deformity correction [7, 12–15]. Our study aimed to analyze the association between surgical correction and quality of life in patients with Blount's disease. We believe that lower limb deformity correction has a beneficial impact on patients' physical and psychological wellbeing, emotions, and social interactions. The scarcity of reports assessing quality of life in patients following lower limb deformity correction prompted us to perform such assessments. We believe that, in addition to the commonly adopted geometric criteria used to assess lower limb alignment, patients' subjective perceptions of their condition and any changes in these perceptions following surgery should be considered.

The purpose of this study was to assess changes in quality of life in patients with tibia vara deformity who underwent intraoperative bilateral reconstructive surgery combined with gradual postoperative correction via the Ilizarov method.

## Material and methods

Our study included 23 patients who had undergone bilateral corrective surgery with the Ilizarov method for varus deformity associated with Blount's disease. The inclusion criteria were: the accessibility of the patient's complete medical and radiographic records, follow-up period of > 1 year, the patient's informed consent, and Short Form (SF)-36 questionnaire completion both prior to and 1 year after surgery. The exclusion criteria were bilateral limb deformities due to other causes (e.g. metabolic diseases such as hypophosphatemic rickets or Paget's disease of bone, the lack of informed consent, and incomplete radiographic records). The study was approved by the Local Institutional Review Board.



**Figure 1.** Bilateral varus deformity, anteroposterior view

The study was conducted in 13 (57%) females and 10 (43%) males at the mean age of 28.43 years (range: 7–60 years) with the mean duration of post-surgery Ilizarov fixator treatment of 106.65 days (range: 31–199 days).

The mean follow-up period was 6.1 years (range: 1.5–10.2 years, SD: 2.88 years).

We evaluated the duration of treatment with an Ilizarov external fixator, the baseline and postoperative values of the medial proximal tibial angle (MPTA), and mechanical axis deviation (MAD). Patients' quality of life was assessed with the SF-36 questionnaire [16].

Preoperative planning was conducted based on panoramic radiographic images of the lower limbs. Obtaining reliable radiographic images requires correct patient positioning, with the patellae facing directly forward. This helps accurately determine the extent of deformity. Corrective surgery is indicated when the MAD exceeds 15 mm.

The obtained radiographic images were used to mark the MPTAs and the center of rotation of angulation (CORA) and to plan the position of the Ilizarov rings. The surgical procedures were conducted under regional anesthesia. During the initial part of the procedure, a 0.5-cm segment of the fibula was resected. Then, a three-ring Ilizarov external fixator was mounted, with the hinges positioned over the predetermined CORA. Once the fixator was in place, proximal tibial corticotomy



**Figure 2.** Bilateral correction of varus deformity using Ilizarov external fixators

was performed through a small incision. Initial deformity correction was performed under fluoroscopy. The same steps were repeated for the other limb (Figure 2).

The patients were mobilized on the first postoperative day and taught how to walk with full weight-bearing using forearm crutches. The patients were discharged on postoperative day 3–5, depending on the progress in their ambulation.

The initial outpatient follow-up assessments were scheduled in 2-week intervals, and the later ones in 4-week intervals. The patients underwent rehabilitation, with exercise therapy targeted at the ankle and knee joints to improve the range of motion and prevent contractures. Over time, as they were making progress in their mobility, the patients were encouraged to walk without crutches or walkers.

The decision to remove Ilizarov fixators was made once clinical and radiographic signs of bone union were observed. First, the fixator was removed from one limb, and the patient was advised to avoid weight-bearing on that limb for 2–4 weeks. Then, 1 month later, the other fixator was removed. This protocol made it easier for patients to walk, while simultaneously allowing the bone regenerate in the other limb to bear progressively more weight during the final weeks of treatment.

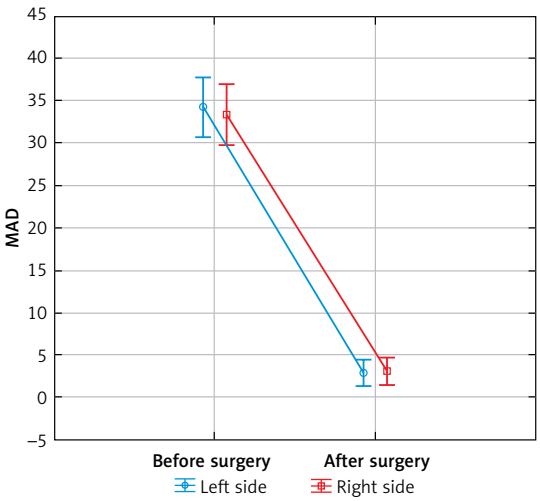


**Figure 3.** Marginal means along with the 95% confidence interval for the variable MAD before and after surgery for the left and right sides

### Statistical analysis

The statistical analysis was conducted using Statistica 13.3 (StatSoft Polska Sp. z o.o, Cracow, Poland) software. Descriptive statistics were calculated, and the mean differences between groups were calculated with a mixed-design analysis of variance model (ANOVA). The level of significance was set at $\alpha = 0.05$.

## Results

Statistical analysis of the MAD values prior to and after left and right knee surgery revealed considerable differences. However, it was only the effect of treatment (i.e. the main effect) that proved significant ($F(1, 44) = 514.12$, $p < 0.001$, $\eta^2 = 0.92$), whereas the interaction effect showed no statistical significance ($F(1, 44) = 0.16$, $p = 0.691$, $\eta^2 < 0.01$). Postoperative MAD values were significantly lower than baseline values, with this difference observed both in the left and right limbs, with no differences between the sides observed at either time point (before or after surgery) (Figure 3).

Statistical analysis of the left and right MPTA values before and after surgery also demonstrated significant differences; however, only the main effect was statistically significant ($F(1, 44) = 514.12$, $p < 0.001$, $\eta^2 = 0.92$), with the interaction effect showing no statistical significance ($F(1, 44) = 0.16$, $p = 0.691$, $\eta^2 < 0.01$). The postoperative MPTA values, both in the left and right limb, were significantly higher, with no differences between the sides (left vs. right) at neither time point (Figure 4).

Changes in the quality of life were analyzed based on SF-36 questionnaire scores. The SF-36 questionnaire includes 8 domains relating to the specific aspects of daily life, including physical and psychological wellbeing, pain, and social functioning.

### Physical functioning

The analysis of baseline and postoperative scores in the female and male groups showed a significant increase in scores, irrespective patient sex ($F(1, 21) = 51.62$, $p < 0.001$, $\eta^2 = 0.71$), with no significant interaction effect ($F(1, 21) = 0.02$, $p = 0.890$, $\eta^2 < 0.01$). No significant differences between the groups were detected at either time point.

### Role limitations due to physical functioning

The scores in this domain of the survey were significantly higher after surgery, irrespective of the sex ($F(1,21) = 48.47$, $p < 0.001$, $\eta^2 = 0.70$), with the interaction effect showing no significance ($F(1, 21) = 0.37$, $p = 0.548$, $\eta^2 = 0.02$). Because the assumptions of homogeneity of variance and normality were violated, the analyses were repeated using a series of nonparametric tests. These yielded the same conclusions: no significant differences between the male and female groups at any study time point. Both groups were found to be similar in terms of baseline scores, postoperative scores, and the values of score changes.

### Role limitations due to emotional problems

The main effect of treatment was also significant for this domain, with the postoperative scores significantly higher than baseline scores ($F(1, 21) = 6.75$, $p = 0.017$, $\eta^2 = 0.24$). This increase was observed in both male and female groups, with no significant interaction effect ($F(1, 21) = 1.75$, $p = 0.200$, $\eta^2 = 0.08$). No significant differences between the groups were detected at either time point.

### Energy/Fatigue

Analysis of pre- and postoperative scores in the female and male groups showed a significant increase in scores, irrespective of the sex ($F(1, 21) = 30.76$, $p < 0.001$, $\eta^2 = 0.59$), with no significant interaction effect ($F(1, 21) = 0.36$, $p = 0.552$, $\eta^2 = 0.02$). This indicates that the changes in scores did not differ significantly between the two groups.

### Emotional wellbeing

The ANOVA results, as in the case of the domains presented above, showed a statistical significance of the effect of treatment (main effect) ($F(1, 21) = 34.68$, $p < 0.001$, $\eta^2 = 0.62$), with no significance of the interaction effect of sex ($F(1, 21) = 0.92$, $p = 0.348$, $\eta^2 = 0.04$). Both groups showed a significant increase in scores for this domain, with no differences between the groups observed either at baseline or after the procedure.

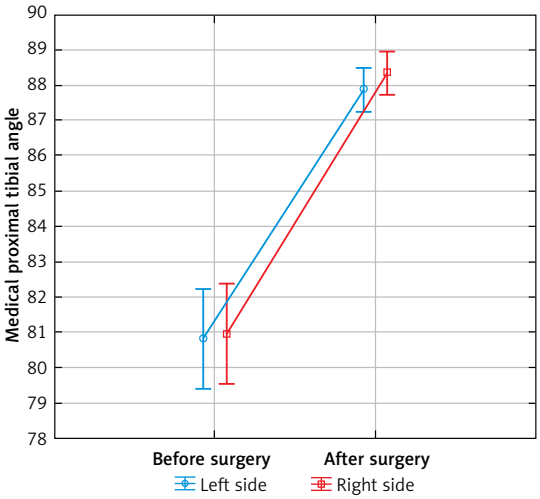


**Figure 4.** Marginal means along with the 95% confidence interval for the variable medial proximal tibial angle before and after surgery for the left and right sides

### Pain

Pain scores also showed a significant effect of treatment (main effect) ($F(1, 21) = 55.07$, $p < 0.001$, $\eta^2 = 0.72$; with the scores significantly higher at the postoperative time point) observed in both male and female groups; with no significant inter-group differences at the two time points (no significant interaction effect) ($F(1, 21) = 1.21$, $p = 0.284$, $\eta^2 = 0.05$).

### Social functioning

Analysis of the baseline and postoperative scores in the male and female groups showed a significant increase, irrespective of the sex ($F(1, 21) = 32.56$, $p < 0.001$, $\eta^2 = 0.61$), whereas the interaction effect was not significant ($F(1, 21) = 1.46$, $p = 0.241$, $\eta^2 = 0.06$). These results indicate that the change in scores did not differ significantly between the groups.

### General health

The general health domain scores were significantly higher after the procedure, irrespective of the sex ($F(1, 21) = 46.06$, $p < 0.001$, $\eta^2 = 0.69$), with the interaction effect showing no significance ($F(1, 21) = 0.94$, $p = 0.344$, $\eta^2 = 0.04$). Both study groups showed similar baseline scores, postoperative scores, and change in scores.

### Health change

The health change domain also showed a significant effect of treatment ($F(1, 21) = 23.74$, $p < 0.001$, $\eta^2 = 0.53$), with significantly higher scores at the second time point; however, the interaction effect was not significant ($F(1, 21) < 0.01$,

$p = 0.999$, $\eta^2 < 0.01$), indicating that the change in scores did not differ significantly between the two groups.

The results are presented in Table I.

Statistical analysis of the obtained SF-36 scores revealed improvements in quality of life across all assessed domains. In addition, the achieved MPTA and MAD fell within the physiological ranges for those parameters.

## Discussion

Orthopedic surgery outcome assessments increasingly include a subjective component in the form of patient-reported outcome measures (PROMs) [17]. These measures use specific questionnaires in which patients describe various aspects of their physical, emotional, and social well-being without supervision by a physician. PROM analysis helps assess the impact of individual procedures on pain severity and quality of life [18–20].

External fixators have been used for lower limb deformity correction for a long time [21–24]. Distraction osteogenesis helps achieve good outcomes in the treatment of congenital and acquired deformities [9, 10, 25–28]. Restoration of a neutral mechanical axis in the lower limb may help reduce abnormal joint loading and pain and improve gait.

Bilateral genu varum deformity may develop in adolescents and adults as a result of Blount's disease, rickets, or skeletal dysplasia [9].

**Table I.** SF-36 scores before and after surgery in all patients and by sex

| Variable | Before surgery | | After surgery | |
|---|---|---|---|---|
| | M | SD | M | SD |
| All patients (*N* = 23) | | | | |
| SF-36 physical functioning | 50.22 | 22.54 | 86.52 | 13.52 |
| SF-36 role limitations due to physical health | 32.61 | 36.49 | 88.04 | 21.15 |
| SF-36 role limitations due to emotional problems | 50.73 | 43.65 | 79.71 | 37.26 |
| SF-36 energy/fatigue | 53.70 | 14.56 | 73.04 | 16.22 |
| SF-36 emotional well-being | 51.48 | 17.98 | 76.87 | 16.27 |
| SF-36 pain | 45.11 | 19.95 | 82.50 | 13.84 |
| SF-36 social functioning | 57.07 | 23.48 | 83.15 | 18.31 |
| SF-36 general health | 33.26 | 22.44 | 66.52 | 16.06 |
| SF-36 health change | 36.96 | 19.76 | 61.96 | 18.26 |
| Women (*n* = 13) | | | | |
| SF-36 physical functioning | 50.00 | 22.17 | 86.92 | 13.00 |
| SF-36 role limitations due to physical health | 34.62 | 34.67 | 94.23 | 10.96 |
| SF-36 role limitations due to emotional problems | 43.60 | 47.89 | 84.62 | 37.55 |
| SF-36 energy/fatigue | 54.23 | 16.94 | 75.38 | 16.52 |
| SF-36 emotional well-being | 50.15 | 19.71 | 79.08 | 16.75 |
| SF-36 pain | 40.77 | 19.75 | 82.88 | 15.06 |
| SF-36 social functioning | 59.62 | 24.56 | 80.77 | 20.17 |
| SF-36 general health | 29.62 | 23.14 | 66.92 | 18.43 |
| SF-36 health change | 34.62 | 19.20 | 59.62 | 19.20 |
| Men (*n* = 10) | | | | |
| SF-36 physical functioning | 50.50 | 24.20 | 86.00 | 14.87 |
| SF-36 role limitations due to physical health | 30.00 | 40.48 | 80.00 | 28.38 |
| SF-36 role limitations due to emotional problems | 60.01 | 37.84 | 73.33 | 37.85 |
| SF-36 energy/fatigue | 53.00 | 11.60 | 70.00 | 16.16 |
| SF-36 emotional well-being | 53.20 | 16.34 | 74.00 | 16.03 |
| SF-36 pain | 50.75 | 19.76 | 82.00 | 12.85 |
| SF-36 social functioning | 53.75 | 22.86 | 86.25 | 16.08 |
| SF-36 general health | 38.00 | 21.76 | 66.00 | 13.29 |
| SF-36 health change | 40.00 | 21.08 | 65.00 | 17.48 |

*M – mean, SD – standard deviation.*

There have been a number of reports on treatment outcomes in unilateral varus deformity correction. However, reports on the simultaneous treatment of both limbs are scarce. Kim *et al.* described their results in 48 patients treated with Ilizarov fixators for bilateral genu varum deformities due to various skeletal dysplasias [28]. Those authors observed a mean lengthening of 7.4 cm and a reduction in MAD of 9.3 mm. Park *et al.* performed 21 genu varum correction surgeries in 11 patients [10]. Those authors achieved a mean reduction in MAD from 28.3 mm to 5.8 mm. Feldman *et al.* treated 19 patients (22 tibiae) with Taylor spatial frames (TSF) [29]. As a result, the MAD was reduced from 53.9 mm to 1.4 mm, and the mechanical MPTA was increased from 71.4 degrees to 87.9 degrees. Li *et al.* reported treatment outcomes in 14 patients with obesity [30]. The postsurgical MAD value decreased from 90 mm to 10 mm, and the mechanical MPTA increased from 66° to 88°.

One of the few studies on bilateral correction of genu varum was conducted by Özkul *et al.* [9]. Those authors performed a gradual correction in 25 patients (50 tibiae) using Smart frame fixators and achieved a considerable improvement in the MAD, mechanical MPTA, and posterior proximal tibial angle (PPTA) values. Those authors emphasized that a gradual correction lowers the risk of such complications as peroneal nerve injury, compartment syndrome, and delayed union.

Our observations do not support this theory, since in our experience, valgus deformity correction surgery is associated with a high risk of peroneal nerve injury. The pressure within the lateral fascial compartment of the leg does not rise significantly during genu varum correction. Thus, our team routinely performs initial varus deformity correction intraoperatively. We believe that this helps the patient to adapt more rapidly to walking with forearm crutches and facilitates rehabilitation. Standing X-ray images help verify the achieved correction, and the degree of patient satisfaction determines whether we decide to further increase or decrease the extent of correction.

In corrective tibial surgery, an issue that continues to provoke discussion is whether or not and, if so, how to perform fibular osteotomy [6, 9, 29]. Sachs *et al.* achieved similar outcomes with and without fibular osteotomy in a small group of patients undergoing deformity correction [6]. Those authors emphasized the risk of peroneal nerve injury depending on the exact location of fibular osteotomy. Eidelman *et al.* performed 10 corrective surgeries without fibular osteotomy in 8 children [31]. MAD correction was achieved using external fixators, with the hinges positioned at the level of the proximal tibiofibular joint. Those authors did not observe any neurological complications. Dilawaiz *et al.* performed 39 corrective surgeries in children [32]. After the procedure, 2 of the patients developed transient sensory and motor dysfunction of the hallux. An analysis of all the cases with neurological complications revealed that the surgeon had performed fibular osteotomy too close to the area deemed to be high-risk according to Kirgis and Albrecht [33]. Cadaveric studies have identified the high-risk zone as the area located 6 cm to 13 cm distal to the fibular head [33, 34].

Our team routinely performs fibular osteotomy during tibial corrective surgery. We use a posterolateral approach at the middle third or at the level of the middle and distal thirds of the fibula. Fibular osteotomy is performed in an oblique, nearly sagittal, rather than transverse plane to allow longitudinal sliding and prevent the fibular bone fragments from impinging on one another other. We have not observed any peroneal nerve dysfunction with this technique.

The most common complication of the Ilizarov method are skin infections at the sites of Kirschner wire insertion [9, 10, 35]. These infections, however, usually respond to oral antibiotics. Five of our patients (21% of the study group) developed skin infection. The rate of inflammatory complications was comparable to that reported in the literature [10, 35, 36]. These complications did not affect the final treatment outcome in any of the patients. We used local antiseptics and oral antibiotic therapy administered for 10–14 days, which was sufficient to control the infection. None of our patients developed osteomyelitis. Moreover, we observed no cases of deep vein thrombosis or neurological dysfunction in the lower limb.

Our findings are similar to or slightly better than those reported in the literature. Detailed data are presented in Table I.

Analysis of changes in quality of life showed a significant improvement in all domains of the SF-36 survey, irrespective of the patient's sex. The results indicated improvements in pain, emotional well-being, and social functioning. The possibility of functioning in society and engaging in any occupation with no disability-associated limitations was an additional benefit after treatment.

Simultaneous surgery of both lower limbs means that the patient must begin to mobilize and bear weight on both limbs immediately after surgery. Our observations indicate that despite the use of the same technique in both limbs, almost always some differences emerge in terms of time of bone-healing time, the rate of functional recovery, and the ability to bear full weight. There seems to be an association between the patient's attitude and pain tolerance and the duration of treatment with an Ilizarov fixator. We suspect




**Figure 5.** Radiograph obtained 1 year after surgery

a correlation between the patient's personality and psychological state and the duration of bone healing and self-discipline during functional recovery. This issue requires further study, including evaluations and analyses, particularly at the time of patient selection for surgery.

Bone regenerate formation also depends on factors that are independent of the patient's attitude towards the therapeutic process. Comorbidities, such as diabetes mellitus or kidney disease, and certain medications may delay bone healing [37]. Our team makes careful, rational judgments when selecting patients for corrective surgery and always considers potential obstacles in the treatment process. Due to its minimally invasive character, the Ilizarov method is particularly suitable for those patients in whom delayed wound healing can be anticipated.

One limitation of our study was the small sample size. This was due to the specific character of the evaluated condition but also the rarity of bilateral deformity correction. Many centers perform corrective osteotomy surgery using internal fixation with plates, which require reduced weight-bearing on the limb for several weeks after surgery. Patients treated with Ilizarov fixators can ambulate with full weight-bearing from postoperative day one; therefore, it is possible to correct both limbs simultaneously without rendering the patient bedridden for long periods.

In conclusion, simultaneous varus deformity correction using Ilizarov external fixators is a safe and effective treatment method. It helps reduce pain and improve gait, which may contribute to improvements in quality of life. The duration of treatment may depend partly on the degree of patient cooperation, attitude, and self-discipline (Figure 5).

## Funding

No external funding.

## Ethical approval

Not applicable.

## Conflict of interest

The authors declare no conflict of interest.

## References

1. Janoyer M. Blount disease. Orthop Traumatol Surg Res 2019; 105 (1S): S111-21.
2. Birch JG. Blount disease. J Am Acad Orthop Surg 2013; 21: 408-18.
3. de Pablos J, Arbeloa-Gutierrez L, Arenas-Miquelez A. Update on treatment of adolescent Blount disease. Curr Opin Pediatr 2018; 30: 71-7.
4. Sabharwal S. Treatment of infantile blount disease: an update. J Pediatr Orthop 2017; 37 Suppl 2: S26-31.
5. Mayer SW, Hubbard EW, Sun D, Lark RK, Fitch RD. Gradual deformity correction in blount disease. J Pediatr Orthop 2019; 39: 257-62.
6. Sachs O, Katzman A, Abu-Johar E, Eidelman M. Treatment of adolescent blount disease using taylor spatial frame with and without fibular osteotomy: is there any difference? J Pediatr Orthop 2015; 35: 501-6.
7. Griswold B, Gilbert S, Khoury J. Opening wedge osteotomy for the correction of adolescent tibia vara. Iowa Orthop J 2018; 38: 141-6.
8. Shiha A, El-Deen MA, Khalifa AR, Kenawey M. Ilizarov gradual correction of genu varum deformity in adults. Acta Orthop Belg 2009; 75: 784-91.
9. Özkul B, Çamurcu Y, Sokucu S, Yavuz U, Akman YE, Demir B. Simultaneous bilateral correction of genu varum with Smart frame. J Orthop Surg 2017; 25: 2309499017713915.
10. Park YE, Song SH, Kwon HN, Refai MA, Park KW, Song HR. Gradual correction of idiopathic genu varum deformity using the Ilizarov technique. Knee Surg Sports Traumatol Arthrosc 2013; 21: 1523-9.
11. Saw A, Phang ZH, Alrasheed MK, Gunalan R, Albaker MZ, Shanmugam R. Gradual correction of proximal tibia deformity for Blount disease in adolescent and young adults. J Orthop Surg 2019; 27: 2309499019873987.
12. Clarke SE, McCarthy JJ, Davidson RS. Treatment of Blount disease: a comparison between the multiaxial correction system and other external fixators. J Pediatr Orthop 2009; 29: 103-9.
13. Burton A, Hennrikus W. Complete closing wedge osteotomy for correction of blount disease (tibia vara): a technique. Am J Orthop 2016; 45: 16-8.
14. Fitoussi F, Ilharreborde B, Lefevre Y, et al. Fixator-assisted medial tibial plateau elevation to treat severe Blount's

disease: outcomes at maturity. Orthop Traumatol Surg Res 2011; 97: 172-8.
15. Jain MJ, Inneh IA, Zhu H, Phillips WA. Tension band plate (TBP)-guided hemiepiphysiodesis in blount disease: 10-year single-center experience with a systematic review of literature. J Pediatr Orthop 2020; 40: e138-43.
16. Kłosiński M, Tomaszewski KA, Tomaszewska IM, Kłosiński P, Skrzat J, Walocha JA. Validation of the Polish language version of the SF-36 Health Survey in patients suffering from lumbar spinal stenosis. Ann Agric Environ Med 2014; 21: 866-70.
17. Wilson I, Bohm E, Lübbeke A, et al. Orthopaedic registries with patient-reported outcome measures. EFORT Open Rev 2019; 4: 357-67.
18. Rolfson O, Eresian Chenok K, Bohm E, et al. Patient-reported outcome measures in arthroplasty registries. Acta Orthop 2016; 87 Suppl 1: 3-8.
19. Dams OC, van den Akker-Scheek I, Diercks RL, et al. The recovery after Achilles tendon rupture: a protocol for a multicenter prospective cohort study. BMC Musculoskelet Disord 2019; 20: 69.
20. Lyman S, Lee YY, Franklin PD, Li W, Cross MB, Padgett DE. Validation of the KOOS, JR: a short-form knee arthroplasty outcomes survey. Clin Orthop Relat Res 2016; 474: 1461-71.
21. Gubin A, Borzunov D, Malkova T. Ilizarov method for bone lengthening and defect management review of contemporary literature. Bull Hosp Jt Dis (2013) 2016; 74: 145-54.
22. Gubin AV, Borzunov DY, Marchenkova LO, Malkova TA, Smirnova IL. Contribution of G.A. Ilizarov to bone reconstruction: historical achievements and state of the art. Strategies Trauma Limb Reconstr 2016; 11: 145-52.
23. Jordan CJ, Goldstein RY, McLaurin TM, Grant A. The evolution of the Ilizarov technique: part 1: the history of limb lengthening. Bull Hosp Jt Dis (2013). 2013; 71: 89-95.
24. Goldstein RY, Jordan CJ, McLaurin TM, Grant A. The evolution of the Ilizarov technique: part 2: the principles of distraction osteosynthesis. Bull Hosp Jt Dis (2013) 2013; 71: 96-103.
25. Vaidya SV, Song HR, Lee SH, Suh SW, Keny SM, Telang SS. Bifocal tibial corrective osteotomy with lengthening in achondroplasia: an analysis of results and complications. J Pediatr Orthop 2006; 26: 788-93.
26. Morasiewicz P, Morasiewicz L, Stępniewski M, et al. Results and biomechanical consideration of treatment of congenital lower limb shortening and deformity using the Ilizarov method. Acta Bioeng Biomech 2014; 16: 133-40.
27. Watanabe K, Tsuchiya H, Sakurakichi K, Yamashiro T, Matsubara H, Tomita K. Treatment of lower limb deformities and limb-length discrepancies with the external fixator in Ollier's disease. J Orthop Sci 2007; 12: 471-5.
28. Kim SJ, Cielo B, Song SH, Song HR, Song SY. Gradual bilateral genu varum correction in skeletal dysplasia using the Ilizarov method. J Orthop Sci 2011; 16: 405-12.
29. Feldman DS, Madan SS, Ruchelsman DE, Sala DA, Lehman WB. Accuracy of correction of tibia vara: acute versus gradual correction. J Pediatr Orthop 2006; 26: 794-8.
30. Li Y, Spencer SA, Hedequist D. Proximal tibial osteotomy and Taylor Spatial Frame application for correction of tibia vara in morbidly obese adolescents. J Pediatr Orthop 2013; 33: 276-81.
31. Eidelman M, Bialik V, Katzman A. The use of the Taylor spatial frame in adolescent Blount's disease: is fibular osteotomy necessary? J Child Orthop 2008; 2: 199-204.
32. Dilawaiz Nadeem R, Quick TJ, Eastwood DM. Focal dome osteotomy for the correction of tibial deformity in children. J Pediatr Orthop B 2005; 14: 340-6.
33. Kirgis A, Albrecht S. Palsy of the deep peroneal nerve after proximal tibial osteotomy. An anatomical study. J Bone Joint Surg Am 1992; 74: 1180-5.
34. Elgafy H, Ebraheim NA, Shaheen PE, Yeasting RA. Extensor hallucis longus innervation: an anatomic study. Clin Orthop Relat Res 2002; 398: 245-51.
35. Adili A, Bhandari M, Giffin R, Whately C, Kwok DC. Valgus high tibial osteotomy. Comparison between an Ilizarov and a Coventry wedge technique for the treatment of medial compartment osteoarthritis of the knee. Knee Surg Sports Traumatol Arthrosc 2002; 10: 169-76.
36. Fadel M, Hosny G. The Taylor spatial frame for deformity correction in the lower limbs. Int Orthop 2005; 29: 125-9.
37. Nicholson JA, Makaram N, Simpson A, Keating JF. Fracture nonunion in long bones: a literature review of risk factors and surgical management. Injury 2021; 52 Suppl 2: S3-11.