

Extremely elevated serum procalcitonin concentration in a patient with stage IV non-small cell lung cancer

Rafał Stando¹, Grzegorz Chmielewski^{1,2}

¹Department of Radiation Oncology, Holycross Cancer Center, Kielce, Poland

²Collegium Medicum, Jan Kochanowski University, Kielce, Poland

Submitted: 21 June 2023; **Accepted:** 11 August 2023

Online publication: 25 August 2023

Arch Med Sci 2023; 19 (5): 1581–1583

DOI: <https://doi.org/10.5114/aoms/170963>

Copyright © 2023 Termedia & Banach

Corresponding author:

Grzegorz Chmielewski MD
Collegium Medicum
Jan Kochanowski University
Department of
Radiation Oncology
Holycross Cancer Center
Kielce, Poland
Phone: +48 512 128 787
E-mail: grzegorz.
chmielewski1@gmail.com

A 65-year-old male with a history of two myocardial infarctions (in 2000 and 2007), atrial fibrillation, hypertension, type 2 diabetes, gout, and prostate hypertrophy presented to the urology outpatient clinic due to hematuria noticed in November 2020. An abnormal growth in the patient's urinary bladder led to transurethral resection of the tumor. Pathology confirmed low-grade papillary urothelial cancer, staged as pTa. Computed tomography (CT) scans of the thorax, abdomen, and pelvis revealed a suspicious mass in the right lung hilum. Positron emission tomography (PET) imaging and bronchoscopy with biopsy were performed. Pathology confirmed a diagnosis of lung adenocarcinoma (Figure 1). The disease was staged as cT4N1M1c, with dissemination to the right adrenal gland and focal metastatic lesions in the abdomen. The patient began chemo-immunotherapy with cisplatin, pemetrexed and pembrolizumab in February 2021. Initially, 4 courses were planned. Treatment tolerance and the patient's condition throughout the courses were satisfactory, with no severe adverse events reported. Restaging examinations performed after the 2nd and 4th courses showed stable disease. A decision had been made to continue treatment with pemetrexed and pembrolizumab.

In April, the patient reported shortness of breath and a productive cough. Tests revealed an increased serum concentration of procalcitonin (PCT) (Table I). However, these symptoms did not correlate with other laboratory tests, such as C-reactive protein (CRP), blood and urinary cultures, physical examination findings, or imaging results. Presence of infection, pulmonary embolism, renal or liver failure, eosinophilia, severe hyperglycemia and medication-related causes were ruled out, indicating the cancer as the cause of elevated PCT. The patient underwent two more courses of systemic treatment but reported worsening of the symptoms in June 2021. The concentrations of PCT were increasing, still without any correlation with CRP or bacteria cultures (Table I). Symptomatic treatment led to remission of the symptoms. Soon after that, the patient reported hemoptysis and was qualified for palliative radiation therapy targeting the right lung tumor. Restaging CT imaging showed progression of the primary tumor and new metastatic lesions in both lungs, left adrenal gland, bones and abdominal subcutaneous tissue. Due to severe pain, he received palliative radiation therapy to C7-Th2 and L1-S1 sections of the spine. In July 2021, second-line single-agent systemic therapy with docetaxel was started but elicited no response. CT scans performed in August 2021 again showed disease progression (Figure 2). PCT was extremely elevated, still without infection symptoms, low CRP

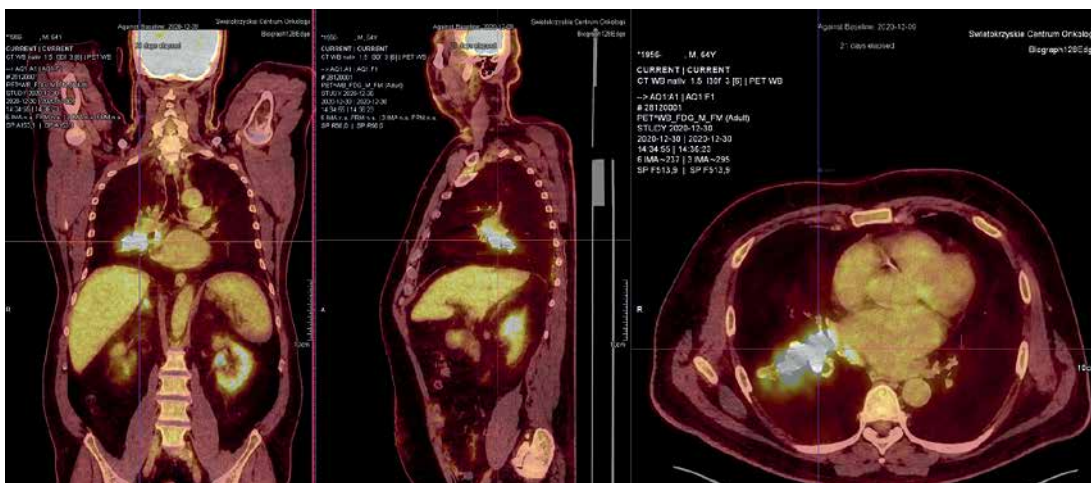

Figure 1. Positron emission tomography with 18F-fluorodeoxyglucose performed during the diagnostic process. A 50 × 92 × 70 cm lesion with increased glucose metabolism is visible, extending from the hilum to the lower lobe of the right lung

Table I. Concentrations of serum procalcitonin at subsequent time points during treatment

Date	Serum procalcitonin [ng/ml] (Normal values: 0.00–0.05 ng/ml)
28.04.2021	9.83
28.04.2021	9.51
10.06.2021	53.45
11.06.2021	47.20
14.06.2021	59.93
15.06.2021	62.01
23.06.2021	72.62
26.08.2021	477.10
29.08.2021	880.16

value and negative blood cultures (Table I). Due to no response to treatment and worsening general condition, best supportive care was introduced. The patient died in September 2021.

Although elevated PCT is often reported in patients with various malignant tumors or other medical conditions, this is the first report of a lung cancer patient presenting with such extremely high concentration of this peptide without associated infection [1–3]. Elevated PCT is a negative prognostic factor in lung cancer patients, as proven in the literature. In the described patient we observed a similar pattern – very limited response to treatment and rapid dissemination of the disease [1, 4, 5]. Kajikawa *et al.* found a significant influence of elevated PCT on overall

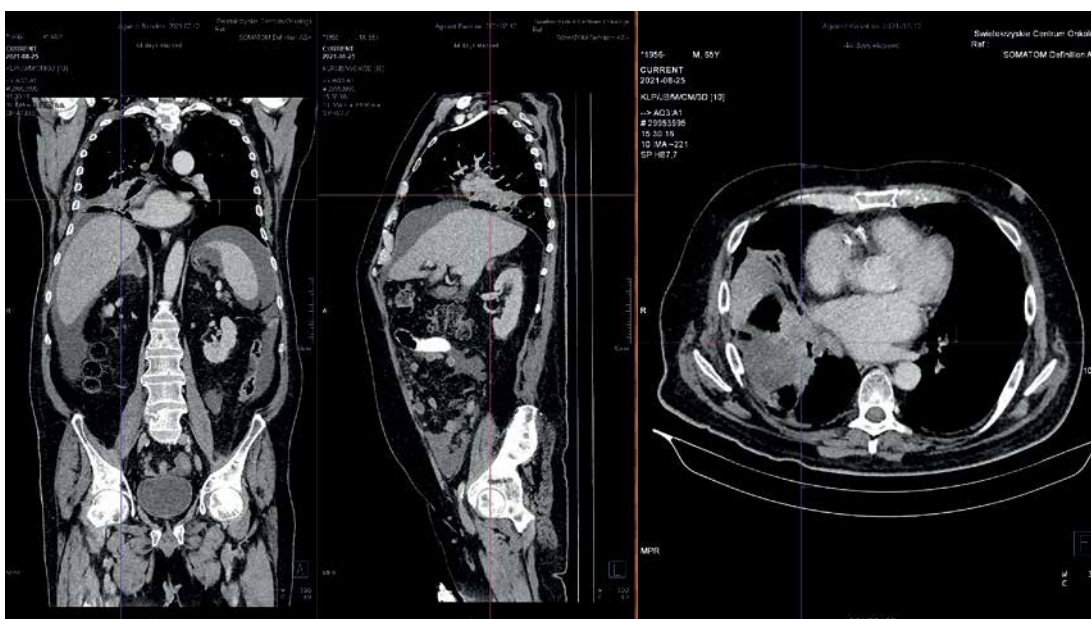


Figure 2. Computed tomography of the thorax, abdomen and pelvis performed after the last line of treatment. Radiology reported enlargement of the tumor of the right lung as well as new metastases to the left and right lung, left adrenal gland, bones and abdominal subcutaneous tissue

survival curves of non-small cell lung cancer (NSCLC) patients when compared with patients without PCT elevation [4]. Additionally, Garoutte *et al.* discovered that among patients with NSCLC, only the ones with liver metastases presented with elevated PCT [5]. Physicians should consider hyperprocalcitoninemia without infection as potentially indicative of the underlying malignant disease.

Conflict of interest

The authors declare no conflict of interest.

References

1. Soeroso NN, Tanjung MF, Afiani D, Pradana A, Tarigan SP, Wahyuni AS. Procalcitonin level in non-small cell lung cancer patients among Indonesian population. *Open Access Maced J Med Sci* 2018; 6: 2123-7.
2. Karagiannis AKA, Girmo-Fragkoulakis C, Nakouti T. Procalcitonin: a new biomarker for medullary thyroid cancer? A systematic review. *Anticancer Res* 2016; 36: 3803-10.
3. Avrillon V, Locatelli-Sanchez M, Folliet L, et al. Lung cancer may increase serum procalcitonin level. *Infect Disord Drug Targets* 2015; 15: 57-63.
4. Kajikawa S, Ohashi W, Kato Y, et al. Prognostic impact of serum procalcitonin in non-small cell lung cancer. *Tumori* 2021; 107: 385-91.
5. Garoutte C, Poulet C, Obstler JB, et al. Procalcitonin serum levels in patients with stage IV non-small cell lung cancer in first line of chemotherapy. *Eur Respir J* 2016; 48 (Suppl 60): 2822.