

Interplay between parathyroid hormone concentration and valvular and aortic calcifications

Anna Olasińska-Wiśniewska^{1*}, Kajetan Grodecki^{2*}, Karolina Jemielity³, Tomasz Urbanowicz^{1,4}, Marcin Misterski¹, Marek Grygier⁵, Piotr Kübler⁶, Bartłomiej Perek¹, Marcin Protasiewicz⁶, Damini Dey⁷, Marek Jemielity¹

¹Department of Cardiac Surgery and Transplantology, Poznan University of Medical Sciences, Poznan, Poland

²First Department of Cardiology, Medical University of Warsaw, Poland

³Department of Radiology, Poznań University of Medical Sciences, Poznan, Poland

⁴Thoracic Research Centre, Collegium Medicum Nicolaus Copernicus University, Innovative Medical Forum, Bydgoszcz, Poland

⁵First Department of Cardiology, Poznan University of Medical Sciences, Poznan, Poland

⁶Institute of Heart Diseases, Wrocław Medical University, Wrocław, Poland

⁷Department of Biomedical Sciences, and Department of Medicine, Cedars-Sinai Medical Center, Biomedical Imaging Research Institute, Los Angeles, CA, USA

***Corresponding author:**

Assist. Prof. Anna Olasinska-Wisniewska
MD, PhD
Department of Cardiac Surgery and Transplantology
Poznan, Poland
E-mail: annaolasinska@ump.edu.pl

Submitted: 18 November 2024; **Accepted:** 28 March 2025

Online publication: 8 June 2025

Arch Med Sci

DOI: <https://doi.org/10.5114/aoms/203473>

Copyright © 2025 Termedia & Banach

Abstract

Introduction: Recently, a relationship between hyperparathyroidism and cardiovascular disorders has been highlighted. The current study aimed to identify a potential relationship between parathyroid hormone (PTH) and valvular calcification performance. A secondary aim was to evaluate the potential association between PTH concentration and post-procedural outcomes after transcatheter aortic valve implantation (TAVI).

Material and methods: Patients with severe symptomatic aortic stenosis were evaluated for study eligibility. Demographics, clinical data, and blood samples were collected. Pre-procedurally, echocardiography and computed tomography (CT) were performed. Quantitative evaluation of calcific tissue was conducted over the three regions of interest – ascending aorta, aortic and mitral valves – using semiautomated software.

Results: The final study group comprised 89 patients (50 females, median (Q1-3) age of 77 (72–82) years. Increased PTH concentration was associated with a higher peak aortic gradient ($p = 0.024$), but not with mean aortic gradient or mitral annular calcification occurrence. CT analysis revealed an association between increased PTH and mean calcific tissue attenuation in the mitral ($p = 0.004$) and aortic valves ($p < 0.001$) and ascending aorta ($p < 0.001$) but no relationship with calcium volume in the regions of interest. Increased PTH did not differ between patients with and without paravalvular leak or new pacemaker implantation.

Conclusions: Increased PTH concentration is associated with calcific tissue attenuation but not calcium volume, suggesting that PTH may influence the degree of calcium accumulation in degenerated regions. PTH could potentially serve as a biomarker of calcific loading in valvular heart disease. However, PTH concentration does not appear to be associated with the rate of complications following TAVI.

Key words: calcification, aortic stenosis, parathyroid hormone, computed tomography.

Introduction

Aortic stenosis is a progressive disease that causes compensatory mechanisms in the heart, including left ventricular hypertrophy and atrial augmentation. Degenerative valve disease is characterized by severe aortic valve calcification involving the leaflets, and the process may also involve the annulus.

In mitral valve degeneration, mitral annular calcification (MAC) may occur, particularly in patients with other degenerative calcifying diseases and well-known cardiovascular factors, such as diabetes, hypertension, hyperlipidemia, and metabolic disorders with calcium-phosphorus imbalance [1]. The calcification is usually located at the posterior mitral annulus, which may affect its whole circumference. The subvalvular apparatus of the mitral valve, mitral leaflets, and commissures are usually spared from calcification [1]; thus, less often, the function of leaflets is impaired, and stenosis occurs.

Recent studies have highlighted a relationship between hyperparathyroidism and cardiovascular disorders [2]. Elevated parathyroid hormone (PTH) levels have been associated with increased cardiovascular morbidity and mortality [2, 3], even in individuals without diagnosed hyperparathyroidism [4]. Several studies have demonstrated an association between increased PTH concentration and greater coronary artery calcification [5–7], both in patients with advanced chronic kidney disease and in those without kidney dysfunction. Moreover, hyperparathyroidism has been independently correlated with impaired coronary flow reserve [8]. The influence of PTH on heart failure development – including heart valve and muscle pathology – has also been reported [9–11]. Additionally, an association has been observed between PTH

levels and the occurrence of atrial fibrillation in patients with aortic stenosis [12].

This study aimed to investigate the potential relationship between PTH levels and valvular calcification in patients with aortic stenosis undergoing transcatheter aortic valve implantation (TAVI). Additionally, the association between PTH and post-procedural outcomes was examined.

Material and methods

One hundred six patients with severe symptomatic aortic stenosis who underwent TAVI between May 2021 and January 2022 in two high-volume structural heart centers, and had available PTH concentration measurements, were evaluated for study eligibility. Seventeen patients were excluded from the study, including 16 due to insufficient imaging for analysis in cardiac tomography or echocardiography and one due to degeneration of a bioprosthetic valve following a previous aortic valve replacement. Additionally, patients undergoing chronic dialysis therapy or those with primary parathyroid gland disorders were excluded from the analysis. Finally, 89 patients – 50 females, 56.2%, median (Q1–3) age of 77 (72–82) years – were included in the study (Figure 1). None had a history of endocrine disorders other than diabetes mellitus, nor were they receiving specific treatment for osteoporosis.

Demographics and clinical data were collected at admission, and blood samples were obtained before the procedure. Serum intact PTH concentrations were measured using an electrochemiluminescence immunoassay kit (Abbott Diagnostics, Abbott Park, IL, USA), with normal reference values ranging from 15 to 68.3 pg/ml.

Echocardiography was performed at admission by an experienced echocardiographer, following a standardized study protocol based on current guidelines for valvular disease management [13, 14]. Routine assessment included aortic stenosis severity based on maximum and mean systolic transvalvular gradients and effective orifice area. Left ventricular contractility and ejection fraction (LVEF) were also evaluated. Pulmonary artery systolic pressure was calculated. Mitral valve disease insufficiency was recorded. If MAC was observed, its grading was based on literature reports [1]. Post-procedural echocardiography was performed at discharge, assessing peak and mean transvalvular gradients as well as paravalvular leak (PVL). PVL was classified into four grades: none, mild, moderate, or severe.

TAVI was performed in the hybrid room under fluoroscopic and echocardiographic guidance by the same team of experienced operators. Transfemoral access was obtained either percutaneously or via surgical cut-down. In cases of severe

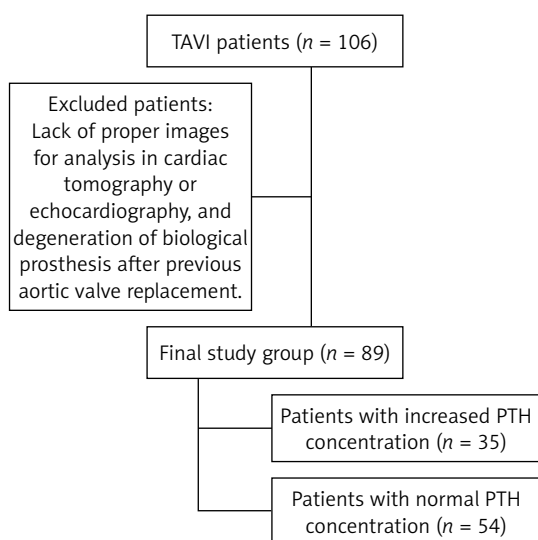


Figure 1. Study flow chart

calcifications, aortic balloon valvuloplasty preceded prosthesis implantation. The implanted aortic prostheses included Evolut R/Pro (Medtronic, Minneapolis, MN, USA), Sapien 3/Sapien 3 Ultra (Edwards Lifesciences, Irvine, CA, USA), Myval (Meril Life Sciences Pvt. Ltd., Gujarat, India), Navitor (Abbott Inc., IL, USA), and Accurate (Boston Scientific, Marlborough, MA, USA). The access site was closed using vascular closure devices or surgical techniques.

Computed tomography

In all patients, contrast-enhanced multislice computed tomography was performed before TAVI. Quantitative evaluation of calcific tissue was conducted over the three regions of interest – ascending aorta, aortic valve, and mitral valve – using semiautomated software (Autoplaque, version 2.51; Cedars-Sinai Medical Center) and a standard mediastinal window (width, 400 HU; level, 40 HU) [15, 16]. The ascending aorta was defined as the segment between the sinotubular junction and the innominate artery. The threshold for calcified plaque was calculated by fitting a Gaussian curve to the image histogram from the aortic regular blood pool (defined by placing a circular region of interest within the ascending aorta) after adjusting with the proximal-to-distal luminal contrast enhancement distribution in the analyzed vessel. The aortic valve was defined as the region between the lower coronary ostium and the virtual basal ring formed by the hinge points of each aortic valve. The mitral valve region was adjusted using a short axis view of the mitral annulus and a stretched view with the exclusion of aortic and left ventricular outflow tract calcium. For calcific tissue quantification in valves, a Gaussian curve was fitted to the smoothed image histogram, the peak value corresponding to normal contrast in the aorta was computed, the lower threshold was set as the 99.7 percentile of blood pool CT attenuation, and all tissue above this threshold was considered calcific.

Statistical analysis

The Shapiro-Wilk test was used to evaluate the data distribution. Normally distributed data were presented as mean and standard deviation (SD). Non-normally distributed data were expressed as the median and 25th–75th percentiles (Q1–Q3). Categorical variables were presented as numbers and percentages. Student's *t*-test was used for normally distributed variables, while the Mann-Whitney test was used for non-normally distributed variables. Kruskal-Wallis ANOVA was used for multigroup analysis. Categorical data

were compared with Fisher's exact test. Correlation analysis (Pearson or Spearman, where applicable) was used to describe the correlation between the variables. Statistical analysis was performed using JASP software (JASP Team; 2020. Version 0.13.1), and $p \leq 0.05$ was considered statistically significant.

Results

All 89 patients presented severe calcified aortic stenosis. The population was burdened with significant co-morbidity rates, including coronary artery disease ($n = 34$, 38.2%), among whom 32 patients had previously undergone coronary angioplasty ($n = 32$, 36%); diabetes or pre-diabetes ($n = 40$, 44.9%); arterial hypertension ($n = 71$, 79.8%); chronic obstructive pulmonary disease (COPD) ($n = 12$, 13.5%); atrial fibrillation ($n = 30$, 33.7%); and chronic kidney disease defined as glomerular filtration rate (GFR) < 60 ml/min/1.73 m² ($n = 41$, 46%). Ten patients had previously undergone pacemaker implantation (11.2%). Increased PTH concentration (over 68.3 pg/ml) was observed in 35 (39.3%) patients.

Echocardiographic results

All patients presented with severe aortic stenosis, with a mean (SD) peak aortic gradient of 89.4 (24) mm Hg, a mean (SD) mean aortic gradient of 56.6 (16.2) mm Hg, a median (Q1–Q3) aortic valve area (AVA) of 0.6 (0.6–0.7) cm², and a median (Q1–Q3) LVEF of 53.6 (50–60)%. In 30 (33.7%) patients, MAC was recorded.

PTH concentration correlated weakly positively with peak aortic gradient ($p = 0.034$, Pearson's $r = 0.225$).

There was no correlation between PTH and mean aortic gradient ($p = 0.142$, Pearson's $r = 0.157$), LVEF ($p = 0.322$, Spearman's $\rho = -0.106$), or pulmonary artery systolic pressure ($p = 0.638$, Spearman's $\rho = 0.058$). Patients with echocardiographic features of MAC did not differ significantly in PTH concentration (median (Q1–Q3) 61.6 (42.9–84.3) vs. 61 (47.5–81.2) pg/ml, $p = 0.788$).

Increased PTH concentration was associated with a higher peak aortic gradient ($p = 0.024$), as presented in Table I.

CT results

Mitral valve mean calcific tissue attenuation ($p = 0.004$), aortic valve mean calcific tissue attenuation ($p < 0.001$), and ascending aorta mean calcific tissue attenuation ($p < 0.001$) differed between patients with increased and normal PTH concentrations (Figure 2, Table II).

PTH concentration correlated positively with aortic valve mean calcific tissue attenuation

Table I. Echocardiographic characteristics of patients with increased and normal PTH concentrations

Parameter	Increased PTH (n = 35)	Normal PTH (n = 54)	P-value
Peak aortic gradient [mm Hg] mean (SD)	96.5 (28.9)	84.8 (19.1)	0.024
Mean aortic gradient [mm Hg] mean (SD)	59.9 (18.8)	54.4 (14)	0.116
LA diameter [mm] mean (SD)	45.2 (5.4)	44.0 (6.1)	0.325
Pulmonary artery systolic pressure [mm Hg] mean (SD)	44.6 (12.6)	42.4 (12.8)	0.493
LVEF (%) median (Q1–Q3)	55 (46.5–60)	60 (53–60)	0.124
Any MAC	13 (37.1%)	17 (31.5%)	0.649

HU – Hounsfield units, LA – left atrial, PASP – pulmonary artery systolic pressure, LVEF – left ventricular ejection fraction, MAC – mitral annular calcification, PTH – parathyroid hormone.

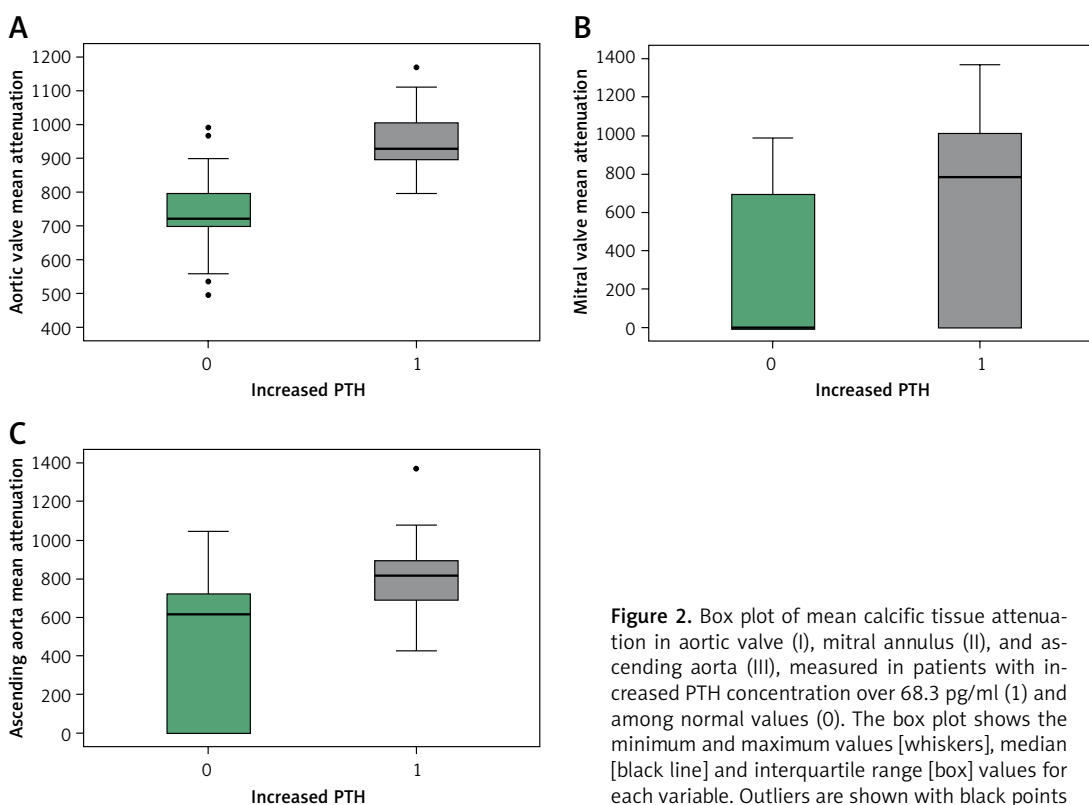


Figure 2. Box plot of mean calcific tissue attenuation in aortic valve (I), mitral annulus (II), and ascending aorta (III), measured in patients with increased PTH concentration over 68.3 pg/ml (1) and among normal values (0). The box plot shows the minimum and maximum values [whiskers], median [black line] and interquartile range [box] values for each variable. Outliers are shown with black points

($p < 0.001$, Spearman's rho = 0.662), mitral valve mean calcific tissue attenuation ($p = 0.022$, Spearman's rho = 0.243), and ascending aorta mean calcific tissue attenuation ($p < 0.001$, Spearman's rho = 0.485) (Figure 3).

Post-procedural prosthesis function and related complications

PTH concentration did not correlate with post-procedural mean ($p = 0.516$, Spearman's rho = -0.078), or peak ($p = 0.960$, Spearman's rho = 0.006) transvalvular gradients.

PTH concentration did not differ in subgroups with no (64.1 (48.5–83.7) pg/ml), mild (58.3 (39.5–77.1) pg/ml), or moderate (77.2 (60.6–87.1) pg/ml) PVL ($p = 0.910$). Increased PTH did not differentiate the subgroups (0.479).

New pacemaker implantation occurred in 14 patients. After excluding patients with previous pacemaker implantation ($n = 10$), subgroups with new implantation ($n = 14$) and without pacemaker implantation ($n = 65$) did not differ in PTH concentration (61.9 (56.2–70.1) vs. 60.1 (43–84.1) pg/ml, $p = 0.842$). The increased PTH group did not differ from the normal PTH group in pacemaker implant rate (0.549).

Discussion

The study revealed associations between PTH concentration and characteristics of valvular and aortic calcifications. This suggests two important considerations: first, a potential role of PTH in the pathophysiology of valvular disease progression, particularly in the development of calcium depos-

Table II. Characteristics of patients with increased and normal PTH concentrations in CT examination

Parameter	Increased PTH (n = 35)	Normal PTH (n = 54)	P-value
Mitral annulus evaluation			
Any MAC, n (%)	19 (54.3)	21 (38.9)	0.192
Mitral valve calcific tissue volume [mm ³] median (Q1–Q3)	3.6 (0–205.7)	0 (0–27.2)	0.233
Mitral valve mean calcific tissue attenuation (HU) median (Q1–Q3)	782.6 (0–1011.5)	0 (0–692.8)	0.004
After excluding patients without MAC			
Parameter	Increased PTH (n = 19)	Normal PTH (n = 21)	P-value
Mitral valve calcific tissue volume [mm ³] median (Q1–Q3)	45.3 (35–860)	466.8 (21–825)	0.688
Mitral valve mean calcific tissue attenuation [HU] median (Q1–Q3)	1006.9 (929.5–1061.4)	781.2 (686.5–815.4)	< 0.001
Aortic annulus evaluation			
Aortic valve calcific tissue volume [mm ³] median (Q1–Q3)	950.2 (527.4–1649.7)	922.2 (534.9–1443.9)	0.576
Aortic valve mean calcific tissue attenuation [HU] median (Q1–Q3)	928.3 (896.3–1004.1)	721.4 (698–796.2)	< 0.001
Ascending aorta evaluation			
Ascending aorta calcific tissue volume [mm ³] median (Q1–Q3)	7.3 (4–11.3)	5.3 (0–11.2)	0.092
Ascending aorta mean calcific tissue attenuation [HU] median (Q1–Q3)	812.7 (690.1–891)	613.4 (0–719.3)	< 0.001
After excluding patients without ascending aorta calcifications			
Parameter	Increased PTH (n = 35)	Normal PTH (n = 36)	P-value
Ascending aorta calcific tissue volume [mm ³] median (Q1–Q3)	7.3 (4–11.3)	10.2 (5.4–14.9)	0.189
Ascending aorta mean calcific tissue attenuation [HU] median (Q1–Q3)	812.7 (690.1–891)	686.6 (627.5–77.45)	0.003

HU – Hounsfield units, MAC – mitral annular calcification, PTH – parathyroid hormone.

its in intracardiac and arterial tissues; and second, the possible utility of PTH as a non-invasive marker of calcific load in valvular heart disease, which could help track the progression of valvular stenosis and aortic degeneration. However, PTH concentration was not useful in identifying patients at higher risk for of PVL or pacemaker implantation. Finally, given the association between PTH and valvular degeneration, further studies are warranted to explore the potential for pharmacological interventions targeting PTH in these patients.

Based on the results of our study, PTH may influence the development of calcific aortic stenosis and mitral annulus calcifications. While we did not assess PTH concentration in patients without aortic stenosis, we observed higher peak transaortic gradients in patients with abnormal PTH concentrations. Additionally, a weak but positive correlation was found between PTH serum concentration and peak systolic transaortic gradient. Increased PTH concentration was specifically associated with more prominent calcific tissue attenuation in all examined regions. We hypothesize

that this observation reflects the progression of mitral annulus and aortic root calcification during the development of aortic valve disease. The association appears not to relate to the volume of calcific tissue but rather to its attenuation or density, suggesting a potential link between PTH and the inflammatory response. Aortic stenosis is a progressive fibrocalcific and inflammatory process characterized by monocyte and macrophage infiltration into valvular tissues, the release of a cytokine cascade, and the subsequent progression to cardiac fibrosis and calcification. This may explain the observed relationship between increased PTH levels and calcific tissue characteristics [17]. As previously reported [18], we observed an increased monocyte-to-lymphocyte ratio in patients with aortic stenosis and impaired contractility.

Valvular aortic pathology involves both inflammatory and mechanical pathomechanisms. Valvular endothelial cells respond morphologically to shear stress [19], undergoing changes due to alterations in mechanical and hemodynamic stimuli. Certain valvular lesions develop preferentially on the leaflet side, exposing these parts to differ-

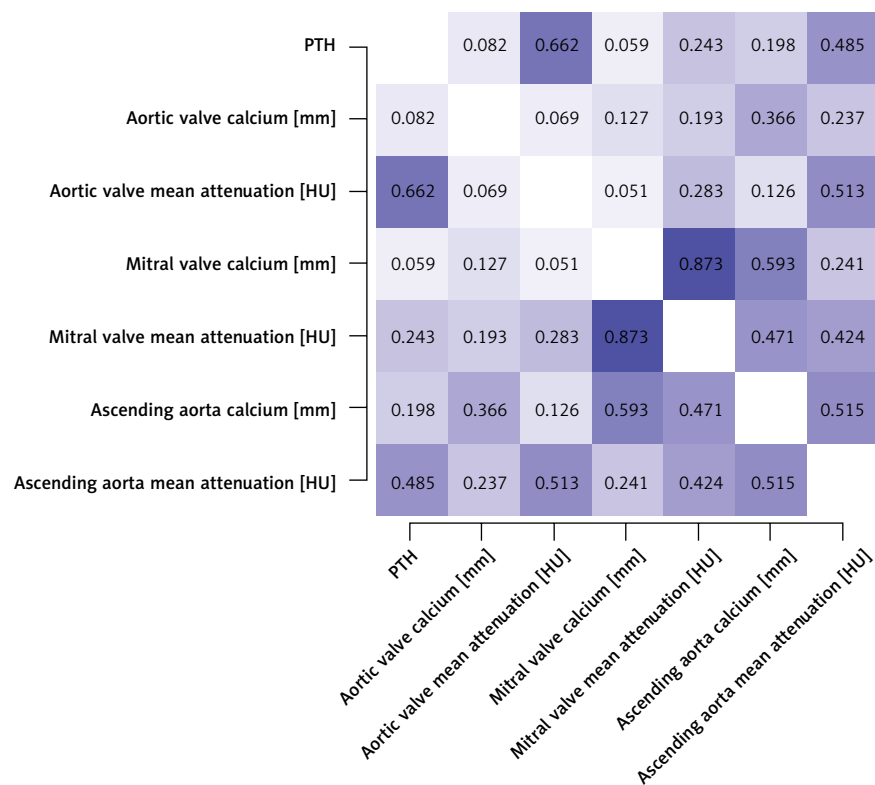


Figure 3. Correlation between PTH concentration and calcific tissue assessment in CT

ent mechanical forces. Notably, velocity gradients are different between the two sides of the leaflet: the inflow surface experiences a strong pulsatile, unidirectional shear stress, while the outflow surface is subjected to much lower recirculating shear stress [19]. Additionally, differences in ventricular and aortic pressure waves create varying profiles for the valvular leaflets and large arteries. As a result, the endothelium on each side of the leaflet experiences different strain patterns. Sclerotic valvular pathology shares similarities with atherosclerosis as the endothelial cells' protective role against interstitial cell activation and calcium accumulation is compromised in a mineral-rich extracellular environment [20]. Valvular endothelial cells become activated with increased expression of monocyte adhesion receptors (VCAM-1, ICAM-1, E-selectin) [21]. It is likely that PTH interferes with these inflammatory processes, promoting increased calcium deposition in altered tissue. PTH receptors are present within the cardiovascular system, including vasculature and heart [22]. PTH induces oxidative stress and necrotic cell death by promoting mitochondrial calcium excess, which subsequently leads to myocardial fibrosis and calcification [23]. The results of our study suggest that PTH is associated with abnormal calcium load in cardiac tissues, rather than the extent of calcifications.

Similar to aortic calcification, our study showed the relationship between increased PTH and cal-

cific tissue attenuation in the mitral valve and ascending aorta. This suggests that PTH may exert a similar effect on other cardiac and arterial regions. In an animal study, Neves *et al.* [24], demonstrated the development of significant aortic medial calcification and coronary calcification in rats following high infusions of synthetic PTH. Undoubtedly, the mechanisms through which PTH acts in different regions of the cardiovascular system and drives calcification require further investigation.

The secondary aim of the study was to analyze the relationship between PTH concentration and post-procedural outcomes. Although PTH levels were associated with characteristics of valvular calcification, they did not correlate with the post-procedural risk of paravalvular leak (PVL) or pacemaker implantation. Previous studies have highlighted the impact of aortic valve calcification on the increased risk of PVL and conduction disturbances [25]. However, our study found no differences in PTH concentration between patients with and without these post-procedural complications. It is important to note that the increase in PTH was associated with calcific tissue density, rather than its volume, which may partly explain these findings. Additionally, other factors, such as the size and type of prostheses, could influence the outcomes.

Based on our study results, we hypothesize that medications affecting PTH concentration may

play a role in managing aortic stenosis. Given the calcific and inflammatory nature of aortic stenosis, which shares pathophysiological similarities with atherosclerosis [26], several therapies proven effective in coronary artery disease [27, 28] have also been explored in aortic stenosis [29, 30]. However, the significant benefits of statin use in coronary artery disease have not been mirrored in valvular disease, as shown in randomized clinical trials such as SEAS, SALTIRE, and ASTRONOMER [31, 32]. Interestingly, recent reports emphasize the role of lipoprotein(a) (Lp(a)) in the progression of aortic stenosis [33, 34]. Genetic variation in the Lp(a) locus lead to elevated plasma Lp(a) levels, which have been associated with a 2-fold increased risk of aortic valve calcification [35]. A post-hoc analysis of the ASTRONOMER study revealed that patients in the highest tertile of Lp(a) levels had a faster echocardiographic progression of aortic stenosis and needed surgery more often [36]. As a result, novel therapies targeting the reduction of Lp(a) levels are being tested for their clinical effectiveness.

In light of our findings, we hypothesize that strategies aimed at modifying abnormal PTH concentration could help prevent calcium accumulation and slow the progression of calcification or valvular pathology. In experimental animal studies, evocalcet, an oral calcimimetic agent that inhibits PTH secretion from parathyroid gland cells, was shown to prevent ectopic calcification in the aorta [37]. Conversely, a case report highlighted the rapid progression of aortic stenosis during treatment with teriparatide, a recombinant form of PTH [38].

A key limitation of our study is the lack of subgroups with normal valves or moderate aortic stenosis and varying PTH concentrations, as well as the absence of long-term follow-up with sequential PTH measurements to assess its influence on the progression of valvular calcification. Additionally, the varying sizes and types of implanted prostheses may have influenced the analysis of post-procedural outcomes.

In conclusion, increased PTH concentration is associated with calcific tissue attenuation but not calcium volume, suggesting that PTH may influence the degree of calcium accumulation in degenerated regions. PTH could potentially serve as a biomarker of calcific loading in valvular heart disease. However, PTH concentration does not appear to be linked to the rate of complications following TAVI.

Acknowledgments

Anna Olasinska-Wisniewska and Kajetan Grodecki – shared first authorship.

Funding

Funded by the National Institute of Health/ National Heart, Lung, and Blood Institute grants (1R01HL148787, R01HL151266, 1R01HL175875) and the Winnick Family Foundation as well as a grant from the Miriam and Sheldon G. Adelson Medical Research Foundation. Kajetan Grodecki is supported by the Polish National Agency for Academic Exchange and the Foundation for Polish Science.

Ethical approval

The Bioethics Committee of the Poznan University of Medical Sciences, Poznan, Poland (No. 272/2021, dated April 8th, 2021) approved the study. The protocol complied with the 1964 Declaration of Helsinki and its later amendments.

Conflict of interest

The authors declare no conflict of interest.

References

1. Van Hemelrijck M, Taramasso M, Gülmez G, Maisano F, Mestres CA. Mitral annular calcification: challenges and future perspectives. *Indian J Thorac Cardiovasc Surg* 2020; 36: 397-403.
2. Trevisan C, Rossi A, Curreri C. Increased parathyroid hormone concentration as a biomarker of atrial fibrillation in severe aortic stenosis: editorial comment. *Kardiol Pol* 2024; 84: 1055-6.
3. Li M, Cheng J, Zhao J, et al. Relationship between intact parathyroid hormone and all-cause death, cardiovascular events, and ectopic calcification in patients with diabetic kidney disease: a retrospective study. *Diabetes Res Clin Pract* 2021; 177: 108926.
4. Hagström E, Hellman P, Larsson TE, et al. Plasma parathyroid hormone and the risk of cardiovascular mortality in the community. *Circulation* 2009; 119: 2765-71.
5. Malluche HH, Blomquist G, Monier-Faugere MC, Cantor TL, Davenport DL. High parathyroid hormone level and osteoporosis predict progression of coronary artery calcification in patients on dialysis. *J Am Soc Nephrol* 2015; 26: 2534-44.
6. Kobayashi T, Kitahara H, Kato K, Saito Y, Kobayashi Y. Impact of parathyroid hormone level on intracoronary calcification and short- and long-term outcomes in dialysis patients undergoing percutaneous coronary intervention. *Circ J* 2023; 87: 247-55.
7. Wu GY, Xu BD, Wu T, et al. Correlation between serum parathyroid hormone levels and coronary artery calcification in patients without renal failure. *Biomed Rep* 2016; 5: 601-6.
8. Osto E, Fallo F, Pelizzo MR, et al. Coronary microvascular dysfunction induced by primary hyperparathyroidism is restored after parathyroidectomy. *Circulation* 2012; 126: 1031-9.
9. Nägele MP, Barthelmes J, Kreysing L, et al. Endocrine hormone imbalance in heart failure with reduced ejection fraction: a cross-sectional study. *Health Sci Rep* 2022; 5: e880.

10. Scicchitano P, Iacoviello M, Passantino A, et al. Plasma levels of intact parathyroid hormone and congestion burden in heart failure: clinical correlations and prognostic role. *J Cardiovasc Dev Dis* 2022; 9: 334.
11. Dahlen B, Müller F, Tröbs SO, et al. Sex-specific relationship between parathyroid hormone and platelet indices in phenotypes of heart failure—results from the MyoVasc Study. *Front Cardiovasc Med* 2021; 8: 682521.
12. Olasińska-Wiśniewska A, Urbanowicz T, Kübler P, et al. Increased parathyroid hormone concentration as a biomarker of atrial fibrillation in severe aortic stenosis. *Kardiol Pol* 2024; 82: 1076-82.
13. Vahanian A, Beyersdorf F, Praz F, et al.; ESC/EACTS Scientific Document Group. 2021 ESC/EACTS Guidelines for the management of valvular heart disease. *Eur Heart J* 2022; 43: 561-632.
14. Salahuddin A, Aronow WS, Spevack DM. At what flow rate does the aortic valve gradient become severely elevated? Implications for guideline recommendations on aortic valve area cutoffs. *Arch Med Sci* 2021; 20: 713-8.
15. Grodecki K, Olasińska-Wiśniewska A, Cyran A, et al. Quantification of aortic valve fibrotic and calcific tissue from CTA: prospective comparison with histology. *Radiology* 2024; 312: e240229.
16. Grodecki K, Tamarappoo BK, Huczek Z, et al. Non-calcific aortic tissue quantified from computed tomography angiography improves diagnosis and prognostication of patients referred for transcatheter aortic valve implantation. *Eur Heart J Cardiovasc Imaging* 2021; 22: 626-35.
17. Mueller KAL, Langnau C, Harm T, et al. Macrophage migration inhibitory factor promotes thromboinflammation and predicts fast progression of aortic stenosis. *Arter Thromb Vasc Biol* 2024; 44: 2118-35.
18. Olasińska-Wiśniewska A, Urbanowicz T, Grodecki K, et al. Monocyte-to-lymphocyte ratio correlates with parathyroid hormone concentration in patients with severe symptomatic aortic stenosis. *Adv Med Sci* 2023; 68: 396-401.
19. Butcher JT, Nerem RM. Valvular endothelial cells and the mechanoregulation of valvular pathology. *Philos Trans R Soc Lond B Biol Sci* 2007; 362: 1445-57.
20. Richards JM, Kunitake JAMR, Hunt HB, et al. Crystallinity of hydroxyapatite drives myofibroblastic activation and calcification in aortic valves. *Acta Biomater* 2018; 71: 24-36.
21. Müller AM, Cronen C, Kupferwasser LI, Oelert H, Müller KM, Kirkpatrick CJ. Expression of endothelial cell adhesion molecules on heart valves: up-regulation in degeneration as well as acute endocarditis. *J Pathol* 2000; 191: 54-60.
22. Goettsch C, Iwata H, Aikawa E. Parathyroid hormone: critical bridge between bone metabolism and cardiovascular disease. *Arterioscler Thromb Vasc Biol* 2014; 34: 1333-5.
23. Fujii H. Association between parathyroid hormone and cardiovascular disease. *Ther Apher Dial* 2018; 22: 236-41.
24. Neves KR, Gracioli FG, dos Reis LM, et al. Vascular calcification: contribution of parathyroid hormone in renal failure. *Kidney Int* 2007; 71: 1262-70.
25. Nusca A, Viscusi MM, Circhetta S, et al. Impact of burden and distribution of aortic valve calcification on the hemodynamic performance and procedural outcomes of a self-expanding, intra-annular transcatheter aortic valve system. *Int J Cardiovasc Imaging* 2024; 40: 2545-58.
26. Yao JQ, Deng ZJ, Fang MX, et al. Expression of serum inflammatory cytokines and oxidative stress markers and their correlation with coronary artery calcium score in patients with coronary heart disease. *Arch Med Sci* 2020; 19: 1709-13.
27. Myśliwiec M, Bandura M, Wołoszyn-Durkiewicz A, et al. 2024 Polish recommendations for the management of familial hypercholesterolemia in children and adolescents. *Arch Med Sci* 2024; 20: 1741-53.
28. Banach M, Surma S, Bielecka-Dąbrowa A, et al. Rosuvastatin-based combination treatment with acetylsalicylic acid or ezetimibe in the management of patients at high and very high cardiovascular risk. Expert Opinion Paper of the Polish Lipid Association 2025. *Arch Med Sci* 2025; 21: 1-15.
29. Marquis-Gravel G, Redfors B, Leon MB, Généreux P. Medical treatment of aortic stenosis. *Circulation* 2016; 134: 1766-84.
30. Afshar M, Yazdan-Ashoori S, Engert JC, Thanassoulis G. Drugs for prevention and treatment of aortic stenosis: how close are we? *Can J Cardiol* 2021; 37: 1016-26.
31. Cowell SJ, Newby DE, Prescott RJ, et al.; Scottish Aortic Stenosis and Lipid Lowering Trial, Impact on Regression (SALTIRE) Investigators. A randomized trial of intensive lipid-lowering therapy in calcific aortic stenosis. *N Engl J Med* 2005; 352: 2389-97.
32. Chan KL, Teo K, Dumesnil JG, Ni A, Tam J; ASTRONOMER Investigators. Effect of Lipid lowering with rosuvastatin on progression of aortic stenosis: results of the aortic stenosis progression observation: measuring effects of rosuvastatin (ASTRONOMER) trial. *Circulation* 2010; 121: 306-14.
33. Sosnowska B, Stepinska J, Mitkowski P, et al. Recommendations of the Experts of the Polish Cardiac Society (PCS) and the Polish Lipid Association (PoLA) on the diagnosis and management of elevated lipoprotein(a) levels. *Arch Med Sci* 2024; 20: 8-27.
34. Santangelo G, Faggiano A, Bernardi N, Carugo S, Giammanco A, Faggiano P. Lipoprotein(a) and aortic valve stenosis: a casual or causal association? *Nutr Metab Cardiovasc Dis* 2022; 32: 309-17.
35. Thanassoulis G, Campbell CY, Owens DS, et al.; CHARGE Extracoronary Calcium Working Group. Genetic associations with valvular calcification and aortic stenosis. *N Engl J Med* 2013; 368: 503-12.
36. Capoulade R, Chan KL, Yeang C, et al. Oxidized phospholipids, lipoprotein(a), and progression of calcific aortic valve stenosis. *J Am Coll Cardiol* 2015; 66: 1236-46.
37. Sakai M, Tokunaga S, Kawai M, et al. Evocalcet prevents ectopic calcification and parathyroid hyperplasia in rats with secondary hyperparathyroidism. *PLoS One* 2020; 15: e0232428.
38. Solomon A, Birkenfeld S. Rapid progression of aortic stenosis after initiation of teriparatide treatment: a case report. *Cardiovasc Endocrinol Metab* 2020; 10: 56-8.