Tuberculous meningitis after allogeneic hematopoietic stem cell transplantation in aplastic anemia: diagnostic challenges and literature review

Yajun Shi[1], Xinchao Ji[2], Rui Song[1], Heng Liu[1], Ying Han[1], Tao Wu[1]*

[1]Department of Hematology, the 940th Hospital of the Joint Logistics Support Force, China
[2]Department of Neurology, Northwest University First Hospital, Xi'an, China

***Corresponding author:**
Tao Wu
Department of Hematology
the 940th Hospital of the
Joint Logistics Support
Force, China
E-mail: wutaozhen@yeah.net

Submitted: 19 April 2026; **Accepted:** 5 October 2026
Online publication: 29 October 2026

Arch Med Sci 2026; 22 (5): 3119–3123
DOI: https://doi.org/10.5114/aoms/241409
Copyright © 2026 Termedia & Banach

Tuberculous meningitis (TBM) is a rare and severe complication after allogeneic hematopoietic stem cell transplantation (allo-HSCT) [1]. Unlike typical cases, the cerebrospinal fluid (CSF) can appear nearly normal, without low glucose or high white blood cells in these patients. Standard diagnostic methods, such as acid-fast staining and culture, frequently fail to detect *Mycobacterium tuberculosis* (*M. tuberculosis*) [2]. Therefore, diagnosing TBM in these patients is very difficult. Metagenomic next-generation sequencing (mNGS) offers a sensitive alternative to these conventional methods. Here, we report a rare case of TBM following allo-HSCT with completely normal CSF glucose and white cell count, diagnosed by mNGS. Because this atypical presentation is easy to overlook, we aim to remind clinicians to suspect TBM even when CSF findings are normal and highlight the critical role of early mNGS in confirming the diagnosis when conventional methods are negative.

A 29-year-old male patient was diagnosed with severe aplastic anemia by bone marrow morphology and biopsy on December 20, 2018 (Figure 1 A). He was a farmer before he fell ill. His cytogenetic results were normal. Despite treatment with cyclosporine and testosterone undecanoate, he remained transfusion dependent. A pre-transplant Tuberculosis-specific enzyme-linked immunospot (T-SPOT.TB) assay for latent tuberculosis infection (LTBI) was negative. On April 2, 2019, he underwent HLA-haploidentical allo-HSCT from a sibling donor, following a Flu/Cy/ATG conditioning regimen.

On March 14, 2020 (post-transplant day 344), the patient presented with intermittent headache, fever and epileptic seizures. Laboratory findings included white blood cells (WBC) 3.41 × 10^9/l, neutrophils (Neu) 1.77 × 10^9/l, lymphocyte (LYM) 1.40 × 10^9/l, hemoglobin (HGB) 52 g/l, platelets (PLT) 4 × 10^9/l, immuglobulin (Ig) G (IgG) 1580.0 mg/dl, IgA 181.0 mg/dl, and IgM 150.0 mg/dl. His laboratory tests were as follows: procalcitonin 4.960 ng/ml, and interleukin-6 35.5 pg/ml. The patient's G test, GM test, blood culture and sputum culture were all negative. He started anti-epileptic therapy with sodium valproate and anti-microbial therapy with imipenem/cilastatin sodium. Despite this treatment, his intermittent fever and seizures persisted.

On March 15, 2020, imaging studies revealed intracranial and pulmonary abnormalities. Cranial MRI showed abnormal signal shadows in the left frontal and occipital lobes with meningeal thickening

Creative Commons licenses: This is an Open Access article distributed under the terms of the Creative Commons Attribution-NonCommercial-ShareAlike 4.0 International (CC BY -NC -SA 4.0). License (http://creativecommons.org/licenses/by-nc-sa/4.0/).

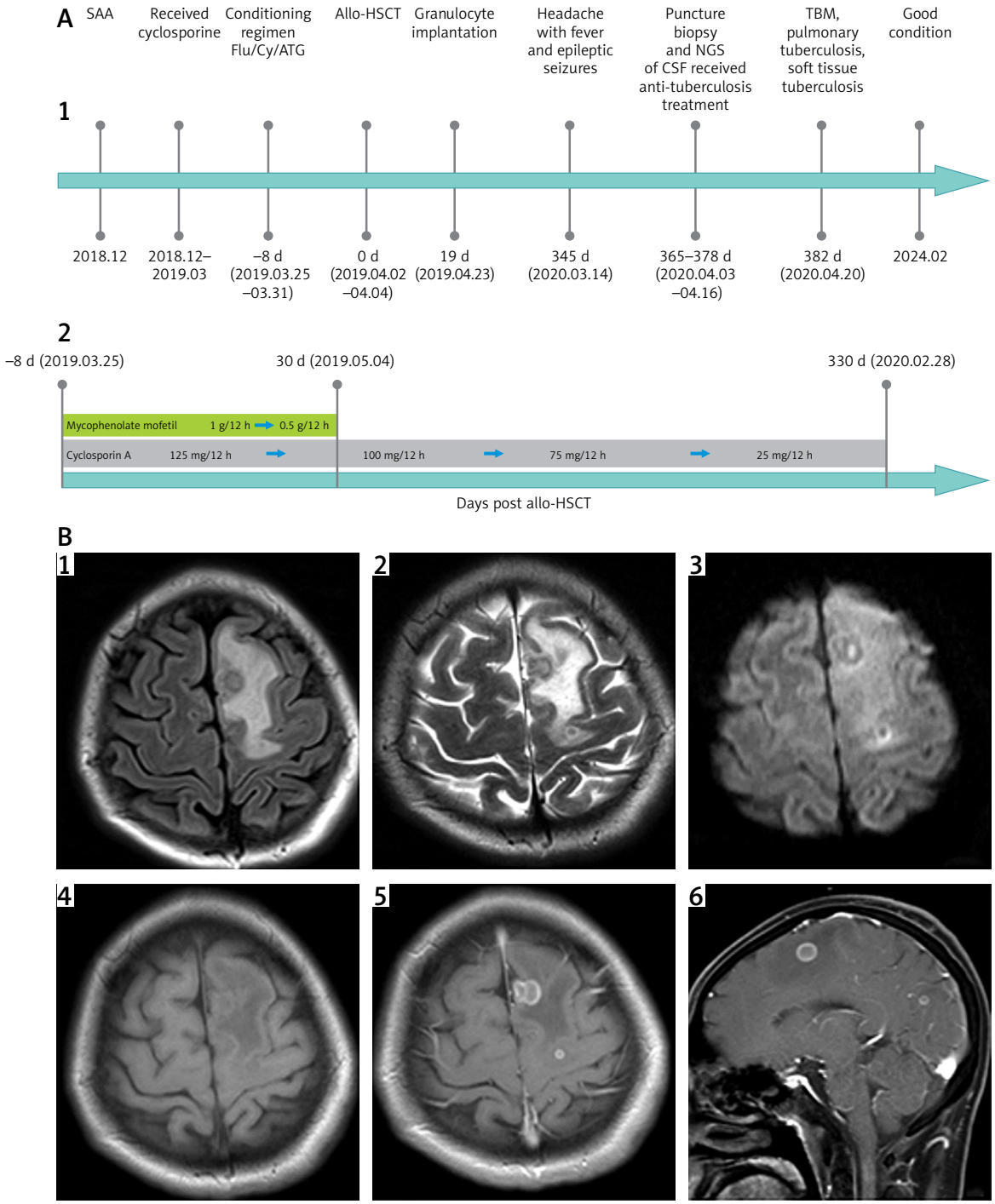

Figure 1. Clinical timeline, neuroimaging, and chest CT of tuberculous meningitis (TBM) following allogeneic hematopoietic stem cell transplantation (allo-HSCT). **A** – Comprehensive clinical timeline and immunosuppressant adjustments. 1) The patient's clinical course, starting from the diagnosis of severe aplastic anemia (SAA) in December 2018, through the preconditioning regimen (fludarabine, cyclophosphamide, and anti-thymocyte globulin [Flu/Cy/ATG]) and allo-HSCT performed on April 2, 2019, to the onset of neurological symptoms (headache, fever, and seizures) on day 344 post-transplantation. It further depicts the initiation of anti-tuberculosis treatment from day 365 to day 378, the subsequent diagnosis of TBM, pulmonary tuberculosis, and soft tissue tuberculosis, and the final clinical remission by February 2024. 2) The progressive tapering of immunosuppressant drugs (mycophenolate mofetil reduced from 1 g/12 h to 0.5 g/12 h, and cyclosporine A decreased from 125 mg/12 h to 25 mg/12 h) from day -3 to day 330 post-allo-HSCT. **B** – Pre-treatment brain magnetic resonance imaging (MRI) performed on day 345 post-transplantation. Cerebral MRI showed abnormal signal shadows in the left frontal and occipital lobes along with meningeal thickening and enhancement. 1) Fluid-attenuated inversion recovery (FLAIR) imaging reveals a hyperintense ring-like lesion in the left frontal lobe. 2) T2-weighted imaging (T2WI) demonstrates prominent perilesional cerebral edema. 3) Diffusion-weighted imaging (DWI) shows a circular hyperintense signal within the lesion, suggesting restricted diffusion. 4) T1-weighted imaging (T1WI) displays a circular hypointense signal. 5) Contrast-enhanced T1WI shows obvious ring enhancement of the lesions, while the surrounding perilesional edema remains unenhanced. 6) Sagittal contrast-enhanced T1WI delineates ring-enhanced lesions in both the left frontal and occipital lobes

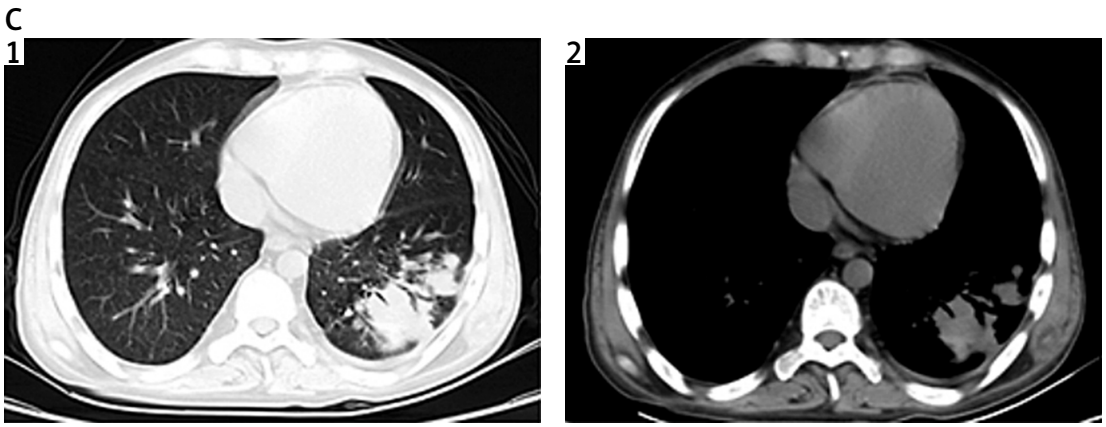

Figure 1. Cont. **C** – Pre-treatment chest computed tomography (CT) performed on day 345 post-transplantation. Chest CT images (1, 2) demonstrate a large, thick-walled cavitary lesion in the right lung with surrounding parenchymal consolidation, which is suggestive of active pulmonary tuberculosis

and enhancement (Figure 1 B: 1-6), while chest computed tomography (CT) was suggestive of pulmonary tuberculosis (Figure 1 C: 1, 2). Lumbar puncture revealed an opening pressure of 140 mm H_2O (reference range: 80–180 mm H_2O), with cerebrospinal fliud (CSF) analysis showing 6 × 10^6/l white blood cells (reference range: 0–5 × 10^6/l), chloride 128.3 mmol/l (reference range: 120–130 mmol/l), glucose 2.88 mmol/l (reference range: 2.5–4.5 mmol/l), and protein 413.0 mg/l (reference range: 80–320 mg/l). Because the patient failed to respond to broad-spectrum antibiotics (imipenem/cilastatin) and antiepileptic drugs, and imaging (chest CT and cranial MRI) suggested possible tuberculosis, we initiated empirical anti-tuberculosis therapy to cover *M. tuberculosis* while awaiting definitive microbiological confirmation. On April 3, 2020, he received oral isoniazid (0.3 g 1/day), rifampicin (0.45 g 1/day), pyrazinamide (0.5 g 3/day), and ethambutol (0.75 g 1/day) in combination with moxifloxacin for diagnostic anti-tuberculosis therapy. Although repeated CSF acid-fast staining remained negative, samples collected from the subcutaneous soft tissue of the back and the cystic mass in the right chest tested positive for acid-fast bacilli staining on April 8, 2020. Subsequently, mNGS of the CSF detected *M. tuberculosis* complex with 47 sequence reads and high confidence. A positive interferon-γ release assay (IGRA), together with the clinical presentation, confirmed the diagnosis of TBM, pulmonary tuberculosis, and soft tissue tuberculosis.

By May 2020, the patient's fever and epileptic seizures had completely resolved, and he returned to his baseline neurological status without any focal deficits. He also became transfusion independent. Long-term follow-up continued until February 2024, at which point he remained in good general and neurological condition without any symptom recurrence.

Discussion. Patients undergoing immune reconstitution after allo-HSCT have a heightened susceptibility to *M. tuberculosis* infection, particularly TBM [1]. TBM occurs when *M. tuberculosis* invades the meninges and brain parenchyma through hematogenous dissemination or by direct invasion of adjacent tissues such as the bones or papillae [3]. Notably, over half of treated TBM patients develop severe neurological complications or death, with delayed diagnosis being a leading contributing factor [4].

This report described a patient with aplastic anemia who developed persistent fever and seizures after allo-HSCT, which were refractory to conventional anti-infective and anti-epileptic therapy. Notably, the diagnosis was challenging. The CSF findings were atypical, and both cultures and acid-fast staining were negative. The patient was ultimately confirmed as TBM through NGS of the CSF, and the patient subsequently showed a good response to anti-tuberculosis treatment.

Clinically, diagnosing TBM is challenging and often delayed, with the primary difficulty being the frequent lack of etiological evidence. However, delayed anti-tuberculosis treatment can cause rapid disease progression, seriously endangering the recipient's life [2]. When such evidence is absent, a clinical diagnosis based on symptoms, CSF parameters, imaging findings, and evidence of tuberculosis at other sites is recommended [5]. Due to the very low positivity rate of traditional methods, especially CSF culture, mNGS has become an important tool for identifying pathogens in CNS infections [6]. Typical CSF changes in TBM include lymphocyte-predominant leukocytosis, decreased glucose, and increased protein, but only one-third of patients present with all three features [7]. TBM with atypical CSF changes may show normal glucose, protein, or white blood cell counts. The present case is particularly noteworthy for its atypical CSF profile, exhibiting isolated hyperproteinorrha-

chia with normal glucose and chloride levels. Therefore, a diagnosis of TBM cannot be excluded based solely on the presence of atypical CSF changes.

There are few reports of TBM after allo-HSCT, and only 3 cases have been specifically described in the literature (Table I) [1, 8, 9]. Yang *et al*. [8] reported that 1,187 patients underwent an interferon-γ release assay (IGRA) before transplantation at a single center in the last 6 years, 18.9% of patients were IGRA-positive, and 5.3% were diagnosed with active tuberculosis after transplantation. Among these, 1 case was diagnosed as TBM and two were suspected, though no detailed reports were provided. Therapeutic regimens for TBM are similar to those for pulmonary tuberculosis but with an extended treatment duration (minimum 12 months), comprising an intensive phase (≥ 2 months) and a consolidation phase (≥ 10 months) [10]. First-line therapy prioritizes blood-brain barrier (BBB)-penetrant agents like isoniazid, rifampicin, pyrazinamide, and ethambutol during initial intensive therapy. In the absence of drug resistance, isoniazid and rifampicin should be used 7 to 10 months after induction therapy [2]. Fluoroquinolones (e.g., levofloxacin, moxifloxacin) are preferred second-line options due to their superior CNS penetration [11]. Emerging oxazolidinones such as contezolid demonstrate enhanced target binding affinity with reduced myelotoxicity [12]. Clinical evidence also supports that adjunctive dexamethasone can assist with anti-inflammatory effects, reduce cerebral edema and intracranial pressure, and improve the survival rate of TBM patients aged ≥ 14 years [13]. The patient in this case received moxifloxacin (a fluoroquinolone) as part of his intensive anti-tuberculosis regimen due to its excellent CNS penetration. He did not receive adjunctive dexamethasone because his initial level of consciousness was normal, and there was no radiological evidence of cerebral edema. Moreover, this case is distinct from the previously reported TBM cases after allo-HSCT (Table I). In our patient, CSF showed normal glucose, normal chloride, and only 6 white blood cells/μl. This pattern is not typical for TBM. Clinicians should be aware that TBM can present with an almost normal CSF

Table I. Clinical characteristics (gender, age, diagnosis, donor type, conditioning intensity, GVHD, IGRA/tuberculosis, time to diagnose TBM, diagnostic basis of TBM, auxiliary tests and examinations) and prognosis of patients (3 cases and this patient reported in the literature) with tuberculous meningitis after allogeneic hematopoietic stem cell transplantation

Variable	Current report	Patient 1 [1]	Patient 2 [8]	Patient 3 [9]
Gender	M	F	F	M
Age [year]	29	25	52	38
Diagnosis	sAA/SAA	MPAL	AML	AML-M5
Donor type	HID	MSD	MSD	MSD
Conditioning intensity	Flu/Cy/ATG	TBI/Cy	Flu/ Bu/ATG	Bu/Cy
GVHD	None	Unknown	None	Grade II aGVHD (the skin and liver)
IGRA/tuberculosis	IGRA negative	Pulmonary tuberculosis	IGRA positive	Unknown
Time to diagnose TBM after allo-HSCT	+344 d	+63 d	+25 d	+145 d
Diagnostic basis of TBM	NGS of CSF revealed the Mtb complex	No	CSF culture/ Mtuberculosis PCR of CSF positive	CSF culture
Auxiliary tests and examinations	The acid-fast staining of pus and soft tissue was positive	MRI showed diffuse leptomeningeal enhancement with microabscesses scattered in the brain	No	Brain CT showed a large intraparenchymal abnormality in the left cerebral hemisphere
Prognosis	Long-term survival	Died owing to TBM	TBM were well controlled, died owing to prolonged thrombocytopenia	Died owing to TBM

M – male, F – female, sAA/SAA – severe aplastic anemia, MPAL – multi-phenotype acute leukemia, AML – acute myeloblastic leukemia, HID – haploidentical donor, MSD – matched sibling donor, Flu – Fludarabine, Cy – cyclophosphamide, ATG – antithymocyte globulin, TBI – total body irradiation, Bu – busulfan, aGVHD – acute graft versus host disease, IGRA – interferon-gamma release assays, CSF – cerebrospinal fluid, PCR – polymerase chain reaction, NGS – next-generation sequencing, Mtuberculosis – M. tuberculosis, TBM – tuberculous meningitis.

profile, especially in immunocompromised hosts. Moreover, the diagnosis was entirely dependent on mNGS, as repeated acid-fast staining and cultures of CSF were persistently negative.

The limitations of this study include the lack of specified protocols for intrathecal injection therapy in TBM.

In conclusion, TBM should be considered in allo-HSCT recipients with persistent fever and neurologic symptoms once common pathogens are excluded. Given the notoriously low sensitivity of conventional acid-fast staining and mycobacterial cultures in this immunocompromised setting, clinicians should not rely solely on these traditional tests to rule out TBM. Instead, early utilization of metagenomic next-generation sequencing (mNGS) of the CSF should be prioritized in the diagnostic workup of such patients. Prompt deployment of mNGS can significantly shorten diagnostic delays and enable the timely initiation of life-saving anti-tuberculosis therapy [13].

Acknowledgments

Yajun Shi, Xinchao Ji and Rui Song contributed equally to the work.

Funding

The work was supported by the following grants: Youth Science and Technology Fund of Gansu (23JRRA321), Innovation Base and Talent Program of Gansu (21JR7RA015), Science and Technology Development Plan Project of Lanzhou (2023-ZD-176), Key Research and Development Program of Gansu Province (22YF7FA106), Hematology Medical Research Center of 940th Hospital of Joint Logistics Support Force (2021yxky078), High-level Talents Project of 940th Hospital of Joint Logistics Support Force (2024-G3-11), Youth Science and Technology Talent Innovation Proj-ect of Lanzhou (2023-QN-16), Science and Technology Program Project of Gansu Province (25JRRA1184), and Natural Science Basic Research Project of Shaanxi Province (2022JQ-859).

Ethical approval

Not applicable.

Conflict of interest

The authors declare no conflict of interest.

References

1. Eom KS, Lee DG, Lee HJ, et al. Tuberculosis before hematopoietic stem cell transplantation in patients with hematologic diseases: report of a single-center experience. Transpl Infect Dis 2015; 17: 73-9.
2. Huynh J, Donovan J, Phu NH, et al. Tuberculous meningitis: progress and remaining questions. Lancet Neurol 2022; 21: 450-64.
3. Schaller MA, Wicke F, Foerch C, et al. Central nervous system tuberculosis: etiology, clinical manifestations and neuroradiological features. Clin Neuroradiol 2019; 29: 3-18.
4. Donald PR, Schoeman JF. Tuberculous meningitis. N Engl J Med 2004; 351: 1719-20.
5. Marais S, Thwaites G, Schoeman JF, et al. Tuberculous meningitis: a uniform case definition for use in clinical research. Lancet Infect Dis 2010; 10: 803-12.
6. Ramachandran PS, Ramesh A, Creswell FV, et al. Integrating central nervous system metagenomics and host response for diagnosis of tuberculosis meningitis and its mimics. Nat Commun 2022; 13: 1675.
7. Patel VB, Burger I, Connolly C. Temporal evolution of cerebrospinal fluid following initiation of treatment for tuberculous meningitis. S Afr Med J 2008; 98: 610-3.
8. Yang J, Moon S, Kwon M, et al. A case of tuberculosis meningitis after allogeneic hematopoietic stem cell transplantation for relapsed acute myeloid leukemia. Transpl Infect Dis 2021; 23: e13482.
9. Aljurf M, Gyger M, Alrajhi A, et al. Mycobacterium tuberculosis infection in allogeneic bone marrow transplantation patients. Bone Marrow Transplant 1999; 24: 551-4.
10. Guillem L, Espinosa J, Laporte-Amargos J, et al. Mortality and sequelae of tuberculous meningitis in a high-resource setting: a cohort study, 1990-2017. Enferm Infecc Microbiol Clin 2024; 42: 124-9.
11. Cresswell FV, Te BL, Atherton R, et al. Intensified antibiotic treatment of tuberculosis meningitis. Expert Rev Clin Pharmacol 2019; 12: 267-88.
12. Li J, Yu Z, Jiang Y, et al. Rare tuberculosis in recipients of allogeneic hematopoietic stem cell transplantation successfully treated with contezolid-a typical case report and literature review. Front Cell Infect Microbiol 2023; 13: 1258561.
13. Ashkin A, Lindner D. The challenges of diagnosing tuberculous meningitis and importance of early intervention. J Community Hosp Intern Med Perspect 2023; 13: 84-7.