Spinal tuberculosis presenting as chronic low back pain and initially misdiagnosed as a lumbar sprain

Caifeng Yan[1], Huibang Liu[2], Huawei He[3], Jie Ma[4], Dewu Bi[5]*

[1]Department of Pharmacy, the Fourth People's Hospital of Nanning, China
[2]Department of Clinical Laboratory, Qingxiu Branch, the First People's Hospital of Nanning, China
[3]Tuberculosis Department, the Fourth People's Hospital of Nanning, China
[4]Department of Surgery, the Fourth People's Hospital of Nanning, China
[5]Department of Clinical Laboratory, the Fourth People's Hospital of Nanning, China

***Corresponding author:**
Dewu Bi MD
Department of Clinical Laboratory
the Fourth People's Hospital of Nanning
China
E-mail: dewubi@163.com

Submitted: 28 July 2026; **Accepted:** 13 October 2026
Online publication: 21 October 2026

Arch Med Sci 2026; 22 (5): 3131–3135
DOI: https://doi.org/10.5114/aoms/241748
Copyright © 2026 Termedia & Banach

Pott's disease, identified by Percival Pott in 1779, is vertebral tuberculosis caused by *Mycobacterium tuberculosis* (*M. tuberculosis*) [1]. Spinal tuberculosis presents a notable global health challenge, representing about 2% of global tuberculosis cases [1].

Magnetic resonance imaging (MRI) is preferred for diagnosis of spinal tuberculosis because it can detect early bone marrow oedema [2]. Additionally, computerised tomography (CT) can guide biopsies and evaluate bony destruction, sequestra, calcified abscesses, and spinal instability that might need surgical intervention. Positron emission tomography computed tomography (PET-CT) is gradually being introduced to distinguish spinal tuberculosis from metastatic disease.

Traditional laboratory tests for spinal tuberculosis lack sensitivity. GeneXpert MTB/RIF is a rapid and reliable diagnostic tool with high sensitivity for detecting *M. tuberculosis* and rifampicin resistance [1]. Interferon-gamma release assays (IGRAs) like T-SPOT.TB can detect latent tuberculosis infection and active spinal tuberculosis but cannot differentiate between them [1, 2].

Diagnosing spinal tuberculosis in elderly patients with chronic back pain can be challenging, as shown by the misdiagnosis that occurs when spinal tuberculosis imitates mechanical back pain, which is often linked to spinal degeneration [3]. The infrequency of spinal tuberculosis in certain areas may cause diagnostic delays, as clinicians may not immediately consider tuberculosis in differential diagnoses for back pain. Moreover, the nonspecific symptoms of spinal tuberculosis can resemble those of other conditions like mechanical back pain or spinal disorders, further complicating accurate diagnosis [4].

Previous studies have suggested that preoperative diagnosis of spinal tuberculosis is difficult, and that it may be easily missed or misdiagnosed [4, 5]. Correct diagnosis has been achieved through surgical intervention and advanced diagnostic procedures including culture and metagenomic next-generation sequencing. This case emphasises the importance of considering tuberculosis in cases of spinal bone destruction when conventional therapies fail, highlighting the critical role of sophisticated diagnostic techniques in identifying the disease. Clinicians should consider symptoms such as chronic back pain, immigration history, or neurological deficits when evaluating spinal tuberculosis. Advanced

Creative Commons licenses: This is an Open Access article distributed under the terms of the Creative Commons Attribution-NonCommercial-ShareAlike 4.0 International (CC BY -NC -SA 4.0). License (http://creativecommons.org/licenses/by-nc-sa/4.0/).

diagnostic methods like metagenomic next-generation sequencing are crucial for timely and accurate identification of tuberculosis and its drug resistance profiles, enabling targeted therapeutic interventions.

This study highlights a case of spinal tuberculosis with atypical presentation, emphasising the risk of premature diagnostic closure due to anchoring bias on a lumbar sprain. Clinicians, especially in emergency departments and primary care, should be cautious as suggestive history or lack of systemic symptoms does not exclude spinal infection. Persistent or unusual low back pain should prompt early reconsideration and timely imaging to prevent vertebral collapse or neurological damage.

A 77-year-old woman was diagnosed with a lumbar sprain at a community health service centre. She had a history of chronic low back pain from weight-bearing activities lasting over 8 months. The timeline of diagnosis and treatment is shown in Figure 1. The patient received symptomatic treatment with advice to rest and avoid heavy lifting. No prescription for prolonged steroids or invasive procedures was given. She was referred to the department of surgery mainly due to back pain. She had a cough but did not experience fever, night sweats, dyspnoea, or weight loss. Her body-temperature was 36.7°C, respiratory rate 20 breaths per minute, blood pressure 120/81 mm Hg, and body mass index 17.26 kg/m^2. Physical examination showed significant tenderness from the 12th thoracic to the first lumbar vertebra. The cough and chest opacities were linked to a concurrent influenza A (H3N2) infection, supported by negative tests for *M. tuberculosis* and positive influenza A (H3N2) results.

Digital radiography revealed compression-related alterations of the T12 and L1 vertebral bodies with adjacent soft-tissue swelling, resulting in secondary narrowing of the spinal canal. Degenerative changes were evident in the lumbar spine: an L4/5 intervertebral disc bulge with protrusion, and disc bulging at L1/2, L2/3, L3/4, and L5/S1. Lumbar osteophytosis was present, and a Schmorl's node was identified in the L2 vertebral body (Figure 2 A). Physical examination revealed tenderness and percussion pain localised to the spinous processes and paraspinal regions of the T12/L1 vertebrae. There was no muscle loss in the lower limbs. Sensory, motor, and blood supply functions of the lower limbs were normal with normal muscle strength and tone. Physiological reflexes were present, but no pathological

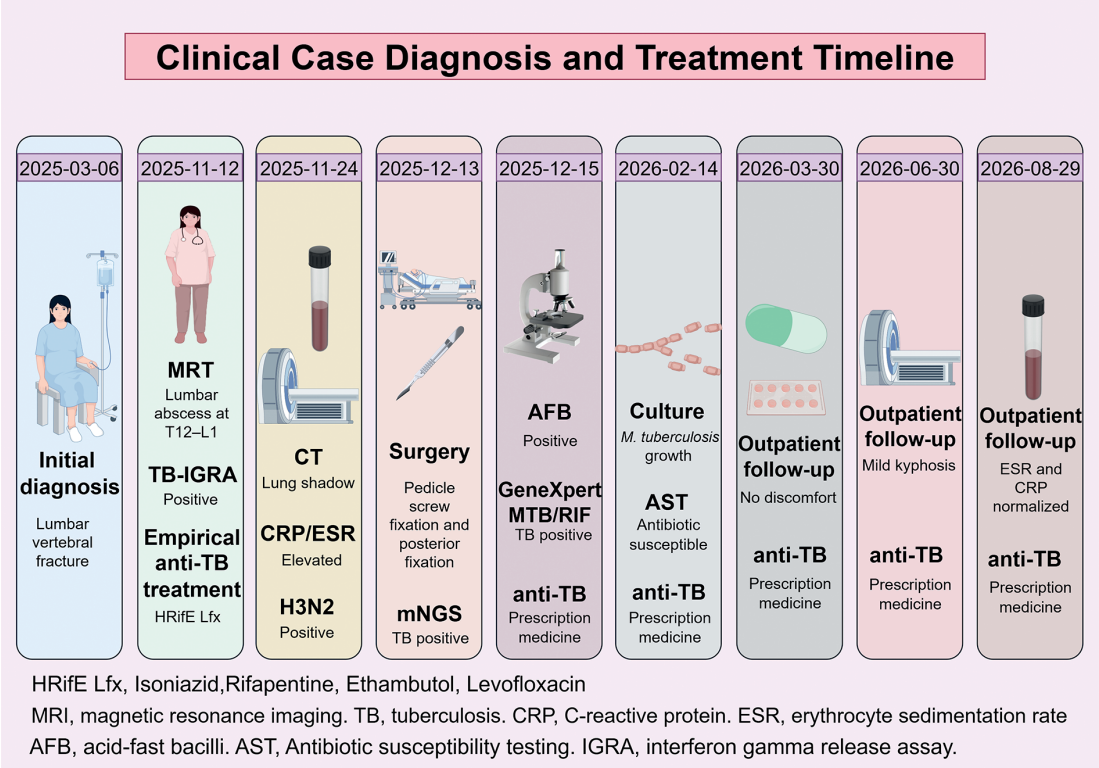

Figure 1. Clinical timeline of the patient with lumbar fracture-associated tuberculosis. The patient first presented with a lumbar fracture on 6 March 2025. Subsequent imaging demonstrated an abscess at T12–L1, and TB-IGRA returned positive alongside raised ESR and CRP. Surgical stabilisation was undertaken on 13 December 2025. Intraoperative samples confirmed *Mycobacterium tuberculosis* by AFB staining, mNGS, and GeneXpert MTB/RIF. Quadruple anti-TB therapy (HRifE-Lfx) was commenced in accordance with drug-susceptibility results. Follow-up to 29 August 2026 showed normalisation of inflammatory markers and progressive clinical recovery

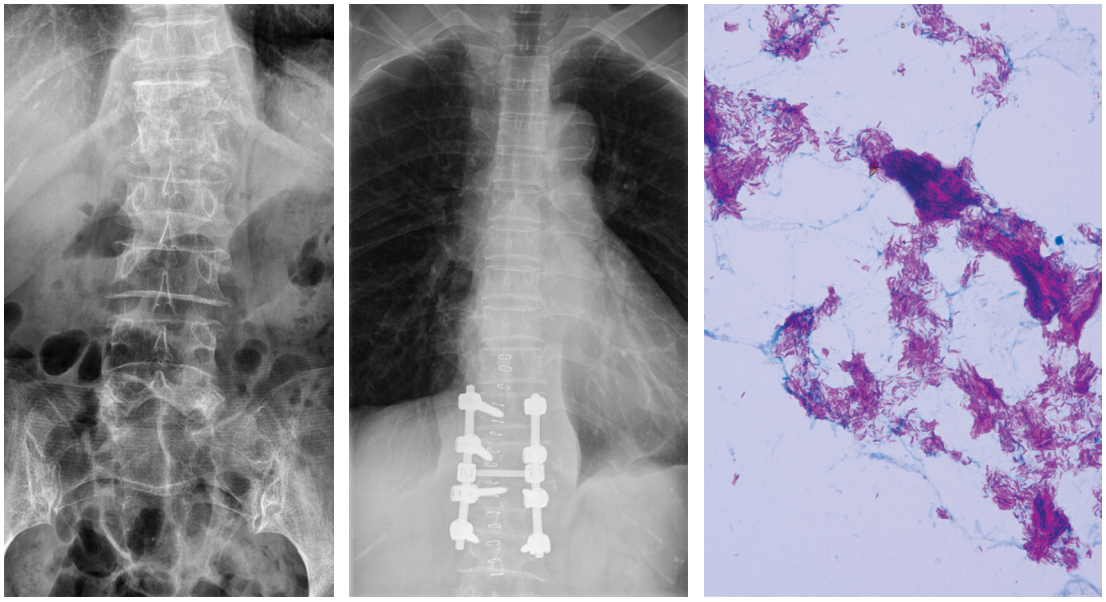

Figure 2. Imaging and microbiological findings in tuberculous spondylodiscitis at the T12-L1 level. **A** – Sagittal T2-weighted MRI of the thoracolumbar junction centred at T12-L1, showing destruction of the anterior T12 and L1 vertebral bodies, narrowing of the T12-L1 disc space, and an anterior prevertebral soft-tissue collection. **B** – Sagittal T2-weighted MRI obtained after posterior pedicle screw-rod fixation at T12-L1, demonstrating the construct in satisfactory position with restored alignment, no breach of screw trajectory, and no hardware failure. **C** – Ziehl-Neelsen stain of the intraoperative specimen (original magnification ×1000), showing beaded, red-staining acid-fast bacilli, consistent with *M. tuberculosis* complex

reflexes were triggered. She received surgery for posterolateral intertransverse lumbar fusion, with foci cleared in the twelfth thoracic and first lumbar vertebrae, and posterior spinal instrumentation was performed (Figure 2 B). A specimen of pus was taken from the patient's lesions. Laboratory investigations showed a positive result for acid-fast bacilli on the pus smears, and *M. tuberculosis* grew in culture from the pus specimen (Figure 2 C). This finding is consistent with the pathogen responsible for the disease, which is *M. tuberculosis*. The diagnosis of tuberculosis spondylitis was confirmed through metagenomic next-generation sequencing, acid-fast bacilli were seen on pus smears, *M. tuberculosis* grew in culture, and GeneXpert MTB/RIF detected *M. tuberculosis* complex DNA and assessed rifampicin resistance. The results of the antibiotic susceptibility tests indicated that the *M. tuberculosis* isolate was sensitive to all the antibiotics tested. The initial prescription of anti-tuberculosis drugs was rifampicin, isoniazid, ethambutol, and levofloxacin; however, since she was an elderly woman with abnormal liver function, the prescribed treatment plan was changed to isoniazid, rifapentine, ethambutol, and levofloxacin. Nine months after the treatment, the patient's back pain resolved without the need for rescue analgesia. Daily activities returned to baseline levels. Inflammatory markers normalised and remained within the normal range. A follow-up MRI on 29 August 2026 showed no progression compared to the baseline. The patient was asymptomatic with mild kyphosis, indicating clinical remission.

Tuberculosis remains a leading cause of death from infectious diseases [6]. Accumulating evidence suggests that the most common symptom reported is pain among spinal tuberculosis [1, 2]. Having limited access to advanced diagnostics in resource-limited settings is common, especially in community health service centres. Lack of diagnostic tools like MRI and GeneXpert contribute to delays and poor treatment outcomes.

Chronic or subacute back pain is frequently initially attributed to mechanical strain, particularly in physically active patients or those with a history of recent exertion [2]. However, such a benign label becomes hazardous when it delays recognition of structural or infectious pathology. In retrospect, several features in this patient should have prompted earlier escalation: pain that persisted or progressed despite rest and conservative measures, focal spinal tenderness on examination, constitutional symptoms, and failure to respond to standard analgesia. In cases of persistent symptoms, a re-evaluation is necessary, including inflammatory marker assessments and targeted MRI scans instead of persisting with the diagnosis of "lumbar strain".

This pitfall is not rare. Spinal infection [2], malignancy [7], and atypical fracture are consistently under-recognised in the early phase precisely because the presenting symptom – back pain – is protean and usually benign. The default assump-

tion that activity-related back pain is self-limiting should be suspended whenever the clinical trajectory diverges from expectation, even if the initial imaging is unremarkable or the patient is otherwise immunocompetent.

Recent advancements in diagnostic modalities are enhancing the timely identification of spinal tuberculosis. The application of metagenomic next-generation sequencing (mNGS) has proven effective in spinal tuberculosis [8–11]. This innovative technology holds promise for expediting diagnoses and enhancing treatment outcomes in elderly individuals with spinal tuberculosis.

Pyogenic spondylodiscitis, often caused by *Staphylococcus aureus* or *Enterobacteriaceae*, typically progresses rapidly and yields growth on routine cultures [12, 13]. In this case, cultures remained sterile, and the clinical course was slower. Metastatic malignancy or primary bone lymphoma can resemble endplate destruction but usually spares the intervertebral disc early and lacks constitutional symptoms. Intraoperative histology showed no signs of neoplasia. An acute osteoporotic vertebral fracture would have presented with mechanical pain following minimal trauma, respecting the disc space without adjacent fluid or epidural features not supported by MRI. Degenerative Modic-type endplate changes produce signal alteration but not the bony destruction or systemic inflammatory response seen here. Brucellar spondylodiscitis, similar to granulomatous spinal infection, was ruled out by negative cultures. Intraoperative findings revealed caseating granuloma with acid-fast bacilli, confirmed by mNGS and Xpert MTB/RIF. This directed antimicrobial treatment and eliminated the need for further sampling.

In conclusion, spinal tuberculosis may present in older adults as persistent, apparently mechanical low back pain without prominent constitutional symptoms. Failure of symptoms to improve, focal vertebral tenderness, or abnormal imaging should prompt further evaluation and tissue diagnosis. In this case, culture and GeneXpert confirmed *M. tuberculosis*, while targeted sequencing provided additional molecular support. The value of NGS should be interpreted in relation to the results of standard microbiological tests and local diagnostic availability.

The limitations of this study deserve consideration. Case reports on spinal tuberculosis are valuable for disseminating unique clinical insights, yet their methodological limitations should be explicitly recognised when interpreting clinical implications. The small sample size and reporting selectivity, where positive or unusual outcomes are more likely to be published than negative or unremarkable cases, introduce selection bias that hinders generalisability and renders these reports unsuitable for calculating population-level epidemiological parameters. Moreover, the typically brief follow-up duration in most published case reports fails to capture essential long-term endpoints, such as neurological and functional recovery post-surgery and anti-TB therapy, due to a lack of long-term follow-up data.

Acknowledgments

Caifeng Yan and Huibang Liu contributed equally.

We are obliged to the patient for giving us permission to disclose her medical information. We sincerely appreciate the involvement of all investigators and nursing staff in this study.

Funding

This study was supported by the Guangxi Zhuang Autonomous Region Health Department (grant number Z-A20241081).

Ethical approval

The study was approved by the Ethics Committee of the Fourth People's Hospital of Nanning, and the patient provided written informed consent to participate in the study in accordance with the Declaration of Helsinki.

Conflict of interest

The authors declare no conflict of interest.

References

1. Glassman I, Nguyen K, Giess J, Alcantara C, Booth M, Venketaraman V. Pathogenesis, diagnostic challenges, and risk factors of Pott's disease. Clin Pract 2023; 13: 155-65.
2. Jain AK, Rajasekaran S, Jaggi KR, Myneedu VP. Tuberculosis of the Spine. J Bone Joint Surg Am 2020; 102: 617-28.
3. Bhute A, Aiyer S, Kanna R. Infection of Lumbar Spine: A Comprehensive Overview. Low Back Ache: A comprehensive guide to management. Springer Nature 2026; 1-33.
4. Chen Y, Wang H. Delayed diagnosis of spinal tuberculosis mimicking spondyloarthritis: a case report. J Med Case Rep 2026; 20: 493.
5. Li T, Liu S. A lumbar drug-resistant tuberculosis: a case report and review of literature. Infect Drug Resist 2024; 17: 5867-73.
6. WHO. Global tuberculosis report 2025. Geneva: World Health Organization; 2025. Licence: CC BY-NC-SA 3.0 IGO.
7. Kienstra GEM, Terwee CB, Dekker FW, et al. Prediction of spinal epidural metastases. JAMA Neurol 2000; 57: 690-95.
8. Cheng H, Wu H, Tan N, et al. Diagnostic efficacy of metagenomic next-generation sequencing in patients with spinal infections: a retrospective study. Infect Drug Resist 2023; 16: 7613-20.

9. Jin Y, Hu S, Feng J, Ni J. Clinical value of metagenomic next-generation sequencing using spinal tissue in the rapid diagnosis of spinal tuberculosis. Infect Drug Resist 2023; 16: 3305-13.
10. Li Y, Yao X, Tang L, et al. Diagnostic efficiency of metagenomic next-generation sequencing for suspected spinal tuberculosis in China: a multicenter prospective study. Front Microbiol 2022; 13: 1018938.
11. Li Z, Wang J, Xiu X, Shi Z, Zhang Q, Chen D. Evaluation of different diagnostic methods for spinal tuberculosis infection. BMC Infect Dis 2023; 23: 695.
12. Placide R, Reznicek J. Evaluation and management of pyogenic spondylodiscitis: a review. J Clin Med 2025; 14: 3477.
13. Skaf GS, Domloj NT, Fehlings MG, et al. Pyogenic spondylodiscitis: an overview. J Infect Public Health 2010; 3: 5-16.