

Cyclophosphamide-rescued plasmapheresis-unresponsive secondary thrombotic thrombocytopenic purpura caused by Sjögren's syndrome

Ting-Yun Lin¹, Chun-Cheng Chang², Chun-Chao Chang³, Jui-Yu Yuan², Hsi-Hsien Chen^{1,3,5}

¹Division of Nephrology, Department of Internal Medicine, Taipei Medical University Hospital, Taipei, Taiwan

²Department of Neurology, Taipei Medical University Hospital, Taipei, Taiwan

³Department of Internal Medicine, School of Medicine, College of Medicine, Taipei Medical University, Taipei, Taiwan

⁴Department of General Medicine, School of Medicine, College of Medicine, Taipei Medical University, Taipei, Taiwan

⁵Department of Primary Care Medicine, Taipei Medical University Hospital, Taipei, Taiwan

Submitted: 4 August 2011

Accepted: 17 November 2011

Arch Med Sci 2012; 8, 5: 934-938

DOI: 10.5114/aoms.2012.30788

Copyright © 2012 Termedia & Banach

Corresponding author:

Dr Hsi-Hsien Chen

Department

of Internal Medicine

Taipei Medical

University Hospital

Taipei, Taiwan

No. 252, Wuxing St

Taipei 11031, Taiwan

Phone: 886-02-27372181

ext 3903

Fax: 886-02-55589890

E-mail: 570713@yahoo.com.tw,

hsihhsien_chen@163.com

Thrombotic thrombocytopenic purpura (TTP) is a rare disorder of blood clotting associated with plasma deficiencies in von Willebrand factor cleaving protease (VWF-CP). The resulting increase in VWF activity leads to excessive microvascular clotting, reduced numbers of circulating platelets, and anemia as a result of physical fibrin-related damage to erythrocytes. Compromised circulation may lead to central nervous system symptoms and kidney failure, and the condition is life-threatening if not recognized and treated immediately [1]. Thrombocytopenia, microangiopathic hemolytic anemia, fever, acute renal dysfunction, and neurological dysfunction are the symptoms that constitute the classical diagnostic pentad for TTP.

The use of therapeutic plasmapheresis has reduced the TTP-related mortality rate from around 80% to 10% [2]. The underlying causes of acquired TTP include hematopoietic stem cell transplantation, pregnancy and oral contraceptives, medications such as antiplatelet agents and quinine, and autoimmune disorders [1].

There are few case reports of secondary TTP induced by Sjögren's syndrome (SS) [3-8]. In these reports, thrombocytopenia and multiple organ dysfunctions were ameliorated after therapeutic plasmapheresis with or without steroid therapy. However, we now present the case of a patient diagnosed with SS-related TTP, exhibiting only three (thrombocytopenia, microangiopathic hemolytic anemia, and neurological dysfunction) of the typical diagnostic symptoms. The 41-year old woman showed a poor response to plasmapheresis and steroids, but was rescued by cyclophosphamide pulse therapy. We also review the literature concerning therapeutic strategies for TTP.

A 41-year-old single woman was admitted exhibiting dulled responsiveness and unexplained mental changes over 2 days. Her speech was slow, irrelevant and incoherent in content, and she exhibited amnesia and generalized malaise and weakness. No other symptoms were identified, and there was no recent history of trauma. The patient had a prior diagnosis of hypertension, which had been controlled for 5 years with atenolol (100 mg daily), and had a baseline blood pressure of around 125/85 mm Hg. There

were no indications of the use of other medications (including herbal and health foods), and no recent history of travel or contact with animals.

The neurologic examination was normal initially, indicating an intact cranial nerve system, full muscle power, and negative meningeal and Babinski signs. A brain magnetic resonance image disclosed neither intracranial hemorrhage nor a space-occupying lesion. Electroencephalography revealed only mild diffuse cortical dysfunction. Only a mild increase in total protein was detected in the cerebrospinal fluid study.

However, by her tenth day in the hospital the patient's consciousness level deteriorated to E2V1M4 (Glasgow Coma Scale: eyes open in response to pain, no verbal response, flexion/withdrawal to pain), and ecchymosis appeared bilaterally over the extremities. A blood examination showed anemia (hemoglobin 5.7 g/dl), thrombocytopenia (platelets 12 000/ μ l), elevated lactate dehydrogenase (LDH 2810 U/l), and fragmented red blood cells in a peripheral blood smear. The prothrombin time (PT) and activated partial thromboplastin time (APTT) were 13.9 s and 31.6 s, respectively. Blood urea nitrogen was 9.96 mmol/l, serum creatinine was 53.38 μ mol/l, and Coombs test was negative. The combination of thrombocytopenia, microangiopathic hemolytic anemia, and acute consciousness impairment of unknown origin caused us to suspect TTP. Daily plasmapheresis therapy was initiated on hospital day 11. This treatment restored the level of consciousness, but the platelet count and LDH levels continued to worsen. Beginning on hospital day 14, methylprednisolone (40 mg, q6h) was administered in conjunction with plasmapheresis, but the platelet level

remained below 20 000/ μ l, and LDH remained above 2000 U/l. At the same time, tests for the anti-nuclear antibodies anti-Ro and anti-La were positive. Under the diagnosis of SS, we began on hospital day 18 to administer intravenous cyclophosphamide (600 mg) followed by oral cyclophosphamide (50 mg, twice daily). The platelet count was elevated on hospital day 20 and gradually increased to 168 000/ μ l on hospital day 41. LDH also returned to a normal range within a few days (Figure 1 and Table I).

Tracing back the history, the patient reported experiencing dry eyes and dry mouth for more than 3 months. Combined with a positive Schirmer's test, salivary scintigraphy and presence of anti-Ro and anti-La, the profile was compatible with SS (Table I). Neither the disintegrin and metalloprotease with thrombospondin type 1 motif, member 13 (ADAMTS13) activity nor autoantibody test was available in our hospital, and although the ADAMTS13 test was available at the National Taiwan University Hospital, the procedure was refused by the patient's family due to cost considerations.

The patient was discharged and the condition was controlled with cyclophosphamide and prednisolone. The platelet count at the 3-month follow-up after discharge was within normal limits.

The mechanistic basis for idiopathic TTP was identified in 1998 when Furlan *et al.* [9] and Tsai and Lian [10] independently described an IgG-antibody-evoked reduction in VWF-CR. The resulting elevation in plasma VWF levels leads to consumptive thrombocytopenia and microangiopathic hemolytic anemia (MAHA), and impaired microvascular circulation can bring on neurological symptoms and acute renal failure [11]. A congenital form of TTP

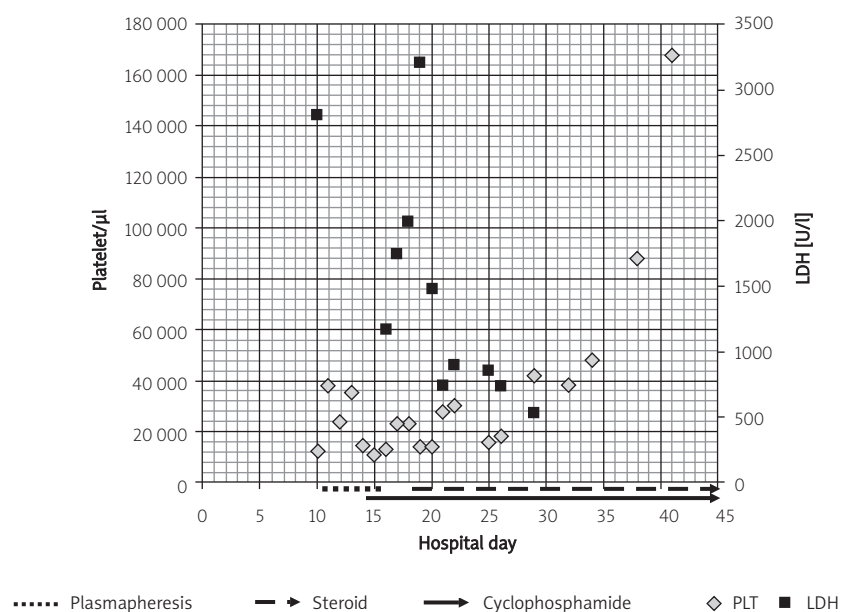


Figure 1. Response of platelet counts and serum lactate dehydrogenase to treatment

Table I. Laboratory data of this patient

Laboratory findings (normal range)	Hospital day 10	Hospital day 41	Discharge day 90
Hematology:			
HGB (12.0-18.0) [g/dl]	5.7		
MCV (80.0-99.0) [fl]	105.3		
PLT (130 000-400 000) [n/μl]	12000	168000	182000
Reticulocytes (0.5-2.5) [%]	19.30		
Blood chemistry		Serology/others	
BUN (2.14-7.14) [mmol/l]	9.96	HG (30-20.0) [μmol/l]	< 0.76
Creatinine (44.20-106.08) [μmol/l]	53.38	Direct Coombs test	(-)
LDH (< 250) [IU/l]	2810	Anti-Ro	(+)
Bilirubin T (< 17.10) [μmol/l]	78.66	Anti-La	(+)
		Antinuclear antibody	1 : 80, (+), speckled
Coagulation		Anti-ds DNA	(-)
PT [s]	13.0	Anti-Sm	(-)
PT-INR (0.78-1.12)	1.3	CEA (< 3.40) [ng/ml]	2.05
APTT (32-45.1) [s]	31.6	CA-125 (< 35.00) [ng/ml]	12.83 U/ml
APTT-R	1.1	CA-199 (< 3.40) [ng/ml]	11.34 U/ml
APTT-control [s]	27.1	Schirmer's test	(+)
		Salivary scintigraphy	(+)
		Peripheral blood smear	Schistocytosis

HGB – hemoglobin, MCV – mean corpuscular volume, PLT – platelets, BUN – blood urea nitrogen, HG – haptoglobin, LDH – lactate dehydrogenase, PT – prothrombin time, PT-INR – international normalized ratio of prothrombin time, APTT – activated partial thromboplastin time, APTT-R – ratio of activated partial thromboplastin time, APTT-control – controlled activated partial thromboplastin time, CEA – carcinoembryonic antigen, CA-125 – cancer antigen 125, CA-199 – carbohydrate antigen 19-9

was described in 2001 by Levy *et al.* [12], who identified mutations in the ADAMTS13 gene that codes for VWF-CP. An ADAMTS13 gene knock-out mouse model was described in 2005 by Motto *et al.* [13]; it revealed that despite undetectable levels of VWF cleaving protease activity, these mice did not develop thrombocytopenia or MAHA unless exposed to Shiga toxin. This provided the first indication that individuals with a congenital ADAMTS13 deficiency may not develop TTP unless exposed to some other triggering event, e.g., infection or pregnancy [14]. Key laboratory findings are the typical peripheral blood smear showing fragmented erythrocytes and thrombocytopenia and anemia with markedly raised serum LDH and normal coagulation parameters, which rule out disseminated intravascular coagulation [7].

Non-idiopathic TTP may be associated with a variety of drugs, infectious agents including HIV, pregnancy, or underlying malignancy [1]. The TTP may also be associated with autoimmune disorders. Systemic lupus erythematosus is the most frequently encountered autoimmune disease associated with TTP, usually occurring in patients with previously diagnosed lupus [15, 16]. Isolated case reports of TTP in patients with scleroderma, rheumatoid arthritis, mixed connective tissue disease, or dermatomyositis have also been reported [11].

In most reported cases there is no evidence that drugs given to treat an autoimmune condition could have triggered the TTP. Reported cases of thrombocytopenia in response to heparin [17], trastuzumab infusion [18], and I125 radiotherapy [19] highlight the importance of considering and investigating potential drug-related thrombocytopenia during diagnosis.

Our patient presented with only three features of the diagnostic pentad of TTP (thrombocytopenia, microangiopathic hemolytic anemia, and neurological dysfunction, without fever or renal dysfunction), but this is common in as many as 70% of TTP cases [20]. As no other cause of TTP was identified after careful evaluation, we conclude that TTP can be added to the list of hematological manifestations associated with SS. This association is apparently very rare, and a review of the literature reveals only six additional cases of TTP associated with SS. These cases are similar in many respects (Table II) but show variability in the extent of hemolysis, the severity of thrombocytopenia, and renal damage. For each patient, fresh plasma exchange (1800 ml) was administered for 6 days beginning on hospital day 11. Plasma exchange treatment was efficacious in three of these cases.

Table II. Comparison of reported patients with thrombotic thrombocytopenic purpura and Sjögren's syndrome

Variable	1 [3]	2 [4]	3 [5]	4 [6]	5 [7]	6 [8]	Present case
Age/sex	61/F	75/F	52/F	54/F	62/F	49/F	41/F
SS duration	7 years	Not previously diagnosed	4 months	3 years	3 months	8 years	Not previously diagnosed
Associated disease	IgM gammopathy monoclonal				Polymyositis hypertension	Rheumatoid arthritis	Hypertension
Presenting symptoms	Fatigue, edema	Gross hematuria	Fatigue, ecchymoses pallor	Headache, fever, nausea, vomiting	Dyspnea	Headache, fever	Disorientation, Fatigue, ecchymoses
Acute renal failure	Presence	Presence	Presence	Presence	Presence	Absence	Absence
CNS involvement	Absence	Absence	Presence	Presence	Absence	Presence	Presence
			Irritability, disorientation	Headache		Headache	Disorientation
Treatment	Plasma-pheresis, steroid	Plasma-pheresis, steroid, dialysis	Plasma-pheresis	Plasma-pheresis, steroid	Plasma-pheresis	Platelet transfusion	Plasmapheresis, steroid, cyclophosphamide
Outcome	Recovery	Died	Recovery 1 relapse	Recovery 3 relapses (recovery by cyclophosphamide)	Died	Died	Recovery

Plasmapheresis has been the first-line therapy for TTP since 1991 and is the only therapy for TTP with proven efficacy in prospective randomized controlled trials [21]. In this process excess VWFs and antibodies against ADAMTS13 are removed from the patient's circulation. Furthermore, the infusion of donor plasma is a source for new ADAMTS13 activity [22]. Corticosteroids are often used in cases of poor response to plasma exchange [23]; however, the additional benefit of corticosteroids has not yet been demonstrated in randomized controlled trials. There is also no consensus in the literature regarding the dose of steroids that should be administered. In refractory or relapsing forms of TTP, sporadic success has been reported with other immune-modulating agents such as vincristine, cyclophosphamide, cyclosporine A, and azathioprine [24, 25]. Rituximab, a monoclonal antibody against the CD20 antigen on B-lymphocytes, depletes the B-cell clone producing ADAMTS13 inhibitory antibodies and has emerged as a new and promising therapy in TTP [26].

This case is the first example of the use of cyclophosphamide to treat the first episode of TTP in an SS patient showing a poor response to plasmapheresis. Whether TTP can be envisaged as an autoimmune disorder remains open; however, in such autoimmune disease-related cases of TTP, cyclophosphamide provides an alternative therapeutic strate-

gy for those patients with a poor response to plasma exchange therapy.

References

- George JN. The thrombotic thrombocytopenic purpura and hemolytic uremic syndromes: overview of pathogenesis (Experience of The Oklahoma TTP-HUS Registry, 1989-2007). *Kidney Int Suppl* 2009; 112: S8-10.
- George JN. Clinical practice. Thrombotic thrombocytopenic purpura. *N Engl J Med* 2006; 354: 1927-35.
- Abe H, Tsuboi N, Yukawa S, et al. Thrombotic thrombocytopenic purpura complicating Sjögren's syndrome with crescentic glomerulonephritis and membranous nephritis. *Mod Rheumatol* 2004; 14: 174-8.
- Campbell GN, Gallo JH. Relapsing thrombotic thrombocytopenic purpura (TTP) in Sjögren's syndrome. *Aust N Z J Med* 1998; 28: 214.
- Koga T, Yamasaki S, Nakamura H, et al. Renal thrombotic microangiopathies/thrombotic thrombocytopenic purpura in a patient with primary Sjögren's syndrome complicated with IgM monoclonal gammopathy of undetermined significance. *Rheumatol Int* 2010. [Epub ahead of print]
- Noda M, Kitagawa M, Tomoda F, Iida H. Thrombotic thrombocytopenic purpura as a complicating factor in a case of polymyositis and Sjögren's syndrome. *Am J Clin Pathol* 1990; 94: 217-21.
- Schattner A, Friedman J, Klepfish A. Thrombotic thrombocytopenic purpura as an initial presentation of primary Sjögren's syndrome. *Clin Rheumatol* 2002; 21: 57-9.
- Steinberg AD, Green WT Jr, Talal N. Thrombotic thrombocytopenic purpura complicating Sjögren's syndrome. *JAMA* 1971; 215: 757-61.

9. Furlan M, Robles R, Galbusera M, et al. von Willebrand factor-cleaving protease in thrombotic thrombocytopenic purpura and the hemolytic-uremic syndrome. *N Engl J Med* 1998; 339: 1578-84.
10. Tsai HM, Lian EC. Antibodies to von Willebrand factor-cleaving protease in acute thrombotic thrombocytopenic purpura. *N Engl J Med* 1998; 339: 1585-94.
11. Parker LS. Thrombotic thrombocytopenic purpura and other forms of nonimmunologic platelet destruction. In: Wintrobe MM, Lee GR (eds), *Wintrobe's clinical hematology*. 10th ed. Williams & Wilkins; Baltimore 1999; 1612-22.
12. Levy GG, Nichols WC, Lian EC, et al. Mutations in a member of the ADAMTS gene family cause thrombotic thrombocytopenic purpura. *Nature* 2001; 413: 488-94.
13. Motto DG, Chauhan AK, Zhu G, et al. Shigatoxin triggers thrombotic thrombocytopenic purpura in genetically susceptible ADAMTS13-deficient mice. *J Clin Invest* 2005; 115: 2752-61.
14. Sarode R. Atypical presentations of thrombotic thrombocytopenic purpura: a review. *J Clin Apher* 2009; 24: 47-52.
15. Brunner HI, Freedman M, Silverman ED. Close relationship between systemic lupus erythematosus and thrombotic thrombocytopenic purpura in childhood. *Arthritis Rheum* 1999; 42: 2346-55.
16. Caramaschi P, Riccetti MM, Pasini AF, Savarin T, Biasi D, Todeschini G. Systemic lupus erythematosus and thrombotic thrombocytopenic purpura. Report of three cases and review of the literature. *Lupus* 1998; 7: 37-41.
17. Ciurzyński M, Jankowski K, Pietrzak B, et al. Use of fondaparinux in a pregnant woman with pulmonary embolism and heparin-induced thrombocytopenia. *Med Sci Monit* 2011; 17: CS56-9.
18. Mantzourani M, Gogas H, Katsandris A, Meletis J. Severe thrombocytopenia related to trastuzumab infusion. *Med Sci Monit* 2011; 17: CS85-7.
19. Makarewicz J, Mikosiński S, Rutkowski A, Adamczewski Z, Lewiński A. Graves' thyrotoxicosis in a patient with metastatic differentiated thyroid carcinoma and chronic lymphocytic leukaemia (CLL). *Arch Med Sci* 2007; 3: 179-84.
20. Thompson CE, Damon LE, Ries CA, Linker CA. Thrombotic microangiopathies in the 1980s: clinical features, response to treatment, and the impact of the human immunodeficiency virus epidemic. *Blood* 1992; 80: 1890-5.
21. Rock GA, Shumak KH, Buskard NA, et al. Comparison of plasma exchange with plasma infusion in the treatment of thrombotic thrombocytopenic purpura. Canadian Apheresis Study Group. *N Engl J Med* 1991; 325: 393-7.
22. Sadler JE, Moake JL, Miyata T, George JN. Recent advances in thrombotic thrombocytopenic purpura. *Hematology Am Soc Hematol Educ Program* 2004; 407-23.
23. Allford SL, Hunt BJ, Rose P, Machin SJ. Guidelines on the diagnosis and management of the thrombotic microangiopathic haemolytic anaemias. *Br J Haematol* 2003; 120: 556-73.
24. Cataland SR, Jin M, Ferketich AK, et al. An evaluation of cyclosporin and corticosteroids individually as adjuncts to plasma exchange in the treatment of thrombotic thrombocytopenic purpura. *Br J Haematol* 2007; 136: 146-9.
25. Fontana S, Kremer Hovinga JA, Lämmle B, Mansouri Taleghani B. Treatment of thrombotic thrombocytopenic purpura. *Vox Sang* 2006; 90: 245-54.
26. George JN, Woodson RD, Kiss JE, Kojouri K, Vesely SK. Rituximab therapy for thrombotic thrombocytopenic purpura: a proposed study of the Transfusion Medicine/Hemostasis Clinical Trials Network with a systematic review of rituximab therapy for immune-mediated disorders. *J Clin Apher* 2006; 21: 49-56.