

# Left atrial mechanical functions in chronic primary mitral regurgitation patients: a velocity vector imaging-based study

Selen Yurdakul, Özlem Yıldırım Türk, Saide Aytekin

Division of Cardiology, Florence Nightingale Hospital, Istanbul, Turkey

**Submitted:** 24 November 2011

**Accepted:** 1 April 2012

Arch Med Sci 2014; 10, 3: 455–463  
DOI: 10.5114/aoms.2014.43740  
Copyright © 2014 Termedia & Banach

**Corresponding author:**

Saide Aytekin MD, Prof. FESC  
Division of Cardiology  
Florence Nightingale Hospital  
Abide i Hurriyet cad. No: 290  
Caglayan Sisli  
34381 Istanbul, Turkey  
Phone: 00902122244950  
Fax: 00902122244982  
E-mail: saideaytekin@gmail.com

## Abstract

**Introduction:** Assessment of the left atrium (LA) mechanical function provides further information on the level of cardiac compensation. We aimed to evaluate LA function using a strain imaging method: velocity vector imaging (VVI) in chronic primary mitral regurgitation (MR).

**Material and methods:** We recruited 48 patients with chronic, isolated, moderate to severe MR (54.70 ± 15.35 years and 56% male) and 30 age- and sex-matched healthy controls (56.52 ± 15.95 years and 56% male). The LA volumes during reservoir (RV), conduit (CV) and contractile phases (AV) were measured. Global strain (S), systolic strain rate (SRs), early diastolic (ESRd) and late diastolic strain rate (LSRd) were calculated.

**Results:** LA RV (50 ± 18.7 to 37.9 ± 5.9;  $p = 0.0001$ ), CV (43.1 ± 29 to 21 ± 2.56;  $p = 0.0001$ ), and AV (17.9 ± 13.5 to 10.9 ± 1.9;  $p = 0.006$ ) were increased in MR patients. The LA reservoir phase strain was 16.2 ± 8.1% in the MR group and 51.1 ± 5.7% in the control group ( $p = 0.0001$ ). The LA SRs (1.01 ± 0.52 s<sup>-1</sup> for MR and 2.1 ± 0.22 s<sup>-1</sup> for controls;  $p = 0.0001$ ), LA ESRd (0.83 ± 0.34 s<sup>-1</sup> for MR and 2.26 ± 0.17 s<sup>-1</sup> for controls;  $p = 0.0001$ ) and LA LSRd (0.76 ± 0.24 s<sup>-1</sup> for MR and 2.2 ± 0.26 s<sup>-1</sup> for controls;  $p = 0.0001$ ) were impaired in MR patients.

**Conclusions:** The LA deformation indices may be used as adjunctive parameters to determine LA dysfunction in chronic primary MR.

**Key words:** chronic mitral regurgitation, left atrium, strain, strain rate.

## Introduction

Left atrium (LA) dilatation is associated with increased cardiovascular mortality and morbidity in patients with chronic mitral regurgitation (MR) [1, 2]. In the pathophysiological process, both the LA and left ventricle (LV) develop adaptive remodelling due to a persistent increase in preload. At early stages, LA plays an important role in the preservation of LV stroke volume by increasing its contractility [3, 4]. However, progressive LA and LV contractile dysfunction is inevitable due to negative myocardial remodelling induced by chronic volume overload in these patients. Early detection of the impairment in LV contractility is important for both determining the optimal time for mitral valve surgery and prognosis of the disease.

Evaluation of the LA mechanical function in chronic MR may give adjunctive information on compensatory mechanisms and subtle changes in LV systolic function. Despite being angle and load dependent, con-

ventional echocardiographic parameters such as LA dimensions, area and volume are widely used to evaluate LA dysfunction in patients with chronic MR. Two-dimensional (2D) strain imaging has emerged as a new technique for the assessment of subclinical cardiac dysfunction with the advantages of being independent from cardiac angle and tethering effects [5–7]. Velocity vector imaging (VVI) is a 2D strain imaging technique which may give detailed information on cardiac regional functions [8, 9].

In this study, we aimed to analyse LA mechanical functions in a cohort of chronic, primary mitral regurgitation patients with normal LV EF, by using both the conventional and VVI-derived strain imaging technique.

## Material and methods

### Study design and patient population

We enrolled 52 patients; however, 4 patients were excluded from the study, due to a bad acoustic window. The study included 48 patients (54.70 ± 15.35 years and 56% male) with asymptomatic, chronic, primary moderate to severe MR and 30 age- and sex-matched control subjects (56.52 ± 15.95 years and 56% male). The aetiologies of MR were determined according to echocardiographic evaluation and identified as follows: mitral valve prolapse (20 patients), degenerative changes (20 patients) and fibrotic changes (8 patients). Inclusion criteria were (1) the presence of non-ischemic moderate to severe MR (the etiology of MR was due to mitral valve prolapse, degenerative changes and fibrotic changes), (2) functional capacity of class I–II according to the New York Heart Association (NYHA), (3) sinus rhythm, (4) normal LV ejection fraction (EF) (≥ 60%). Among the study group, 25 patients had normal coronary arteries based on coronary angiographic examination, 15 patients had a negative exercise test and 8 patients had no clinical features of coronary artery disease (CAD). None of the patients had wall motion abnormality on echocardiographic examination. Patients with LV EF under 60%, coexistence of aortic valve disease of more than a mild degree, mitral stenosis, known or suspected CAD, low quality echocardiographic image for VVI analysis, patients with atrioventricular conduction abnormalities and atrial fibrillation were excluded from the study. Subjects in the control group had no clinical feature of CAD; also they had none of the cardiovascular risk factors. All of them were asymptomatic (functional capacity of class I) and had normal echocardiographic findings.

The study protocol was approved by the local Ethics Committee of our institute, and detailed written informed consent was obtained from each

patient. The study was performed in accordance with the Declaration of Helsinki.

### Echocardiographic measurements

Patients underwent transthoracic echocardiography (Siemens, Sequoia, C256; Mountain View, CA, USA) using a 2.3–3.5 MHz transducer. Left ventricular end-diastolic (LVEDD) and end-systolic diameters (LVESD), interventricular septum (IVS) and posterior wall (PW) thickness were measured from the parasternal long-axis view using M-mode [10]. From the apical four-chamber view, LV end-diastolic and end-systolic volumes (LVEDV and LVESV), LV stroke volume (LV SV) and LV EF were calculated using modified Simpson's method [10]. Peak early (E) (m/s) and late diastolic (A) (m/s) transmitral flow velocities were also analysed. The LA horizontal systolic diameter was measured from the apical 4-chamber view. Maximal (max), minimal (min) and pre-atrial LA volumes and areas were determined by the biplane area-length method [11]. The LA max volume (Volmax) was measured in ventricular end-systole just before mitral valve opening, min volume (Volmin) after mitral valve closure, and pre-atrial volume (Volpre) at the onset of the “p” wave on the electrocardiogram (ECG). LA volume index (LAVI) was calculated by dividing Volmax by body surface area (BSA). In addition, using LA volumes, the following LA dynamic volumes were also calculated: a) LA reservoir volume: Volmax-Volmin, b) LA conduit volume: LV total stroke volume-LA reservoir volume, c) LA contractile volume: Volpre-Volmin.

The degree of mitral regurgitation was identified using mitral regurgitant volume (RV). Mitral RV was quantified according to previously published guidelines [12, 13].

### Tissue Doppler imaging

Guided by the apical 4-chamber view, a 5 mm sample volume was placed just apical to the medial and lateral mitral annulus, identified using pulsed-wave tissue Doppler imaging (TDI). Settings were adjusted for a frame rate between 120 and 180 frame/s and a cine loop of 3 to 5 consecutive heart beats was recorded. TDI-derived indices – peak velocity during systolic ejection (S'), peak early (Ea), late diastolic (Aa) mitral annular velocities and Ea/Aa ratio – were measured. Mitral E/E' ratio was calculated as previously described. Tei index was calculated as the sum of isovolumetric contraction time (IVCT) and isovolumetric relaxation time (IVRT) divided by ejection time (ET). All the measurements were taken from three consecutive cycles, and the average of three measurements was calculated.

Aiming to evaluate atrial segmental function, we also recorded apical 4 and 2 chamber views of both atria and determined sampling points for each basal, mid and superior atrial segment from septal, lateral, anterior and inferior walls of the LA. The peak atrial early ( $V_E$ ) and late ( $V_A$ ) velocities were measured from each segment and average values were calculated.

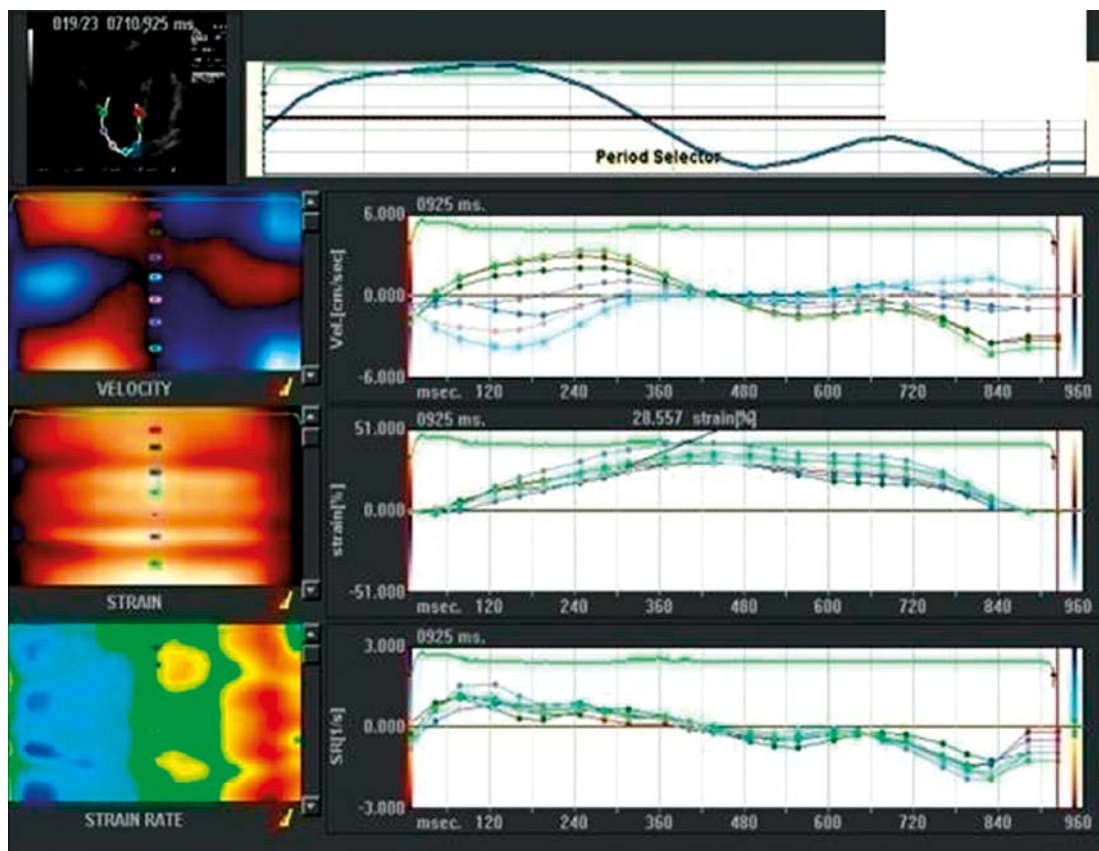
### Velocity Vector imaging

Grey-scaled, 2-D apical 4- and 2-chamber views of the LA were recorded. The frame rate was kept between 70 Hz and 100 Hz and 1 beat acoustic capture function was used. We analysed LA deformation offline by using the VVI software (Syngo VVI, Siemens Medical Solutions, Germany). After the endocardial borders were defined manually by the user for LA, VVI software automatically tracked LA endocardial borders throughout the cardiac cycles and the velocity vectors were occurred (Figure 1). Then we manually determined the sampling points for basal, mid and superior atrial segments from septal, lateral, anterior and inferior walls for the LA, during ventricular systole and at early and late diastole. Identifying the cardiac phases of systole and diastole, we measured the aortic valve closure time (AVC) and the time

interval from the beginning of the QRS wave on ECG to peak E wave and to peak A wave, respectively on Doppler images. Consequently, strain and strain rate curves were automatically developed by the VVI software.

“Strain” and “strain rate” are defined as the change in the relative distance between localized tracked trace points, combined with the difference in the relative displacement of tissue motion behind the tracked points. Strain was defined as the instantaneous local trace lengthening or shortening, and SRs as the rate of lengthening or shortening [11]. Global strain (S), systolic strain rate (SRs), early diastolic (ESRd) and late diastolic strain rate (LSRd) were calculated by averaging the data revealed from all segments analysed in LA. Peak systolic strain and SRs were used to evaluate atrial reservoir function, ESRd was used to determine atrial conduit function and LSRd was used for the atrial contractile function [14].

We also analysed LV deformation properties to evaluate subclinical LV systolic dysfunction. Apical four-chamber, two-chamber and long-axis views were recorded for the LV VVI analysis. Segmental analysis was performed according to the 16-segment LV model of the American Society of Echocardiography [15]. Averages of the 16 segments were calculated as the global LV systolic S and SRs.



**Figure 1.** The colour M-mode echocardiography map and time curves showing LA velocity, strain (%), and strain rate (1/s) curves in the apical four-chamber view

## Reproducibility

Intra-observer and inter-observer variability for VVI measurements were assessed. For intra-observer variability, a sample of 10 VVI measurements was randomly selected and examined by the same observer in two different days. For inter-observer variability, a second observer blind to the clinical information and to the results of the first observer's results examined the same 10 measurements. Intraclass correlation coefficients for the same observer and different observers were calculated [16].

## Statistical analysis

Statistical data were analysed with the Statistical Package for the Social Sciences 16.0 (SPSS, Chicago, IL, USA) program. Results were expressed as means and standard deviations. Paired samples *t*-test was used for comparisons of the groups.

Correlation analyses were derived using Pearson analysis. The results were considered significant when the *p* value was less than 0.05.

## Results

### Clinical characteristics and conventional echocardiographic data

Table I shows the clinical characteristics and conventional echocardiographic parameters of the patients and the control group. As expected, LV dimensions and LA volumes were all increased in the patients.

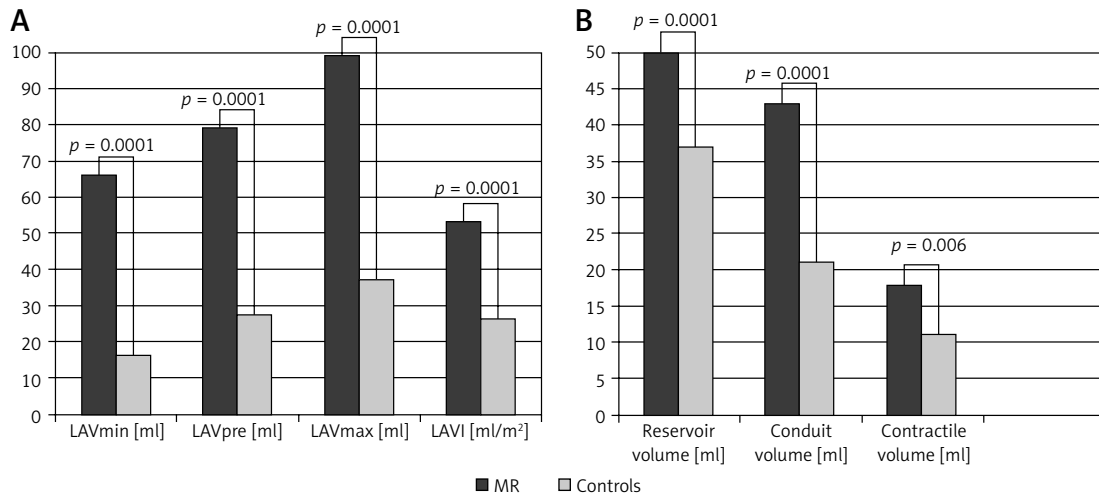
### Left atrium functional analysis

Left atrial dynamic volumes during reservoir (RV), conduit (CV) and contractile phases (AV) were also increased (LA RV (50 ±18.7 ml to 37.9 ±5.9 ml; *p* = 0.0001), CV (43.1 ±29 ml to 21 ±2.56 ml;

**Table I.** Clinical and conventional echocardiographic parameters

| Parameter             | MR group (n = 48) | Control group (n = 30) | Value of <i>p</i> |
|-----------------------|-------------------|------------------------|-------------------|
| Age [years]           | 54.70 ±15.35      | 56.52 ±15.95           | 0.61              |
| Male [%]              | 56                | 56                     | 0.79              |
| SBP [mm Hg]           | 130 ±12.2         | 130 ±13.8              | 0.78              |
| DBP [mm Hg]           | 69.5 ±12.3        | 70.3 ±12.5             | 0.85              |
| HR [bpm]              | 74.2 ±1.8         | 72.5 ±1.3              | 0.83              |
| BSA [m <sup>2</sup> ] | 1.76 ±0.17        | 1.74 ±0.15             | 0.50              |
| LVEDD [cm]            | 5.38 ±0.70        | 4.78 ±0.32             | 0.0001            |
| LVESD [cm]            | 3.83 ±0.64        | 3.5 ±0.72              | 0.03              |
| IVS [cm]              | 1.01 ±0.11        | 1.01 ±0.11             | 0.97              |
| PW [cm]               | 1.1 ±1.09         | 0.97 ±0.13             | 0.46              |
| LVEDV [ml]            | 118 ±40           | 95.16 ±10.44           | 0.003             |
| LVESV [ml]            | 54.6±29.08        | 34.90 ±5.94            | 0.0001            |
| EF [%]                | 60.50 ±5.13       | 62.30 ±10.85           | 0.11              |
| RV [ml]               | 52.16 ±10.1       | –                      |                   |
| Peak E [m/s]          | 0.76 ±0.28        | 0.61 ±0.35             | 0.047             |
| Peak A [m/s]          | 0.79 ±0.25        | 0.65 ±0.41             | 0.056             |
| E/A ratio             | 1.04 ±0.29        | 1.00 ±0.40             | 0.657             |
| DT [ms]               | 190.3 ±49         | 97.7 ±19.4             | 0.0001            |
| IVRT [ms]             | 156.5 ±16.9       | 76.7 ±11.6             | 0.0001            |
| LA diameter [cm]      | 4.86 ±0.77        | 3.78 ±0.30             | 0.0001            |

Results was presented as mean ± SD, MR – mitral regurgitation, HR – heart rate, SBP – systolic blood pressure, DBP – diastolic blood pressure, LVEDD – left ventricle end diastolic diameter, LVESD – left ventricle end systolic diameter, IVS – interventricular septum diastolic diameter, PW – posterior wall diastolic diameter, LVEDV – left ventricle end diastolic volume, LVESV – left ventricle end systolic volume, EF – left ventricle ejection fraction, RV – regurgitant volume, E – early diastolic velocity, A – late diastolic velocity, DT – deceleration time, IVRT – isovolumetric relaxation time



**Figure 2.** Comparisons of left atrial static and volume characteristics among study groups

$p = 0.0001$ ), AV ( $17.9 \pm 13.5$  ml to  $10.9 \pm 1.9$  ml;  $p = 0.006$ ) in MR patients compared to controls (Figure 2).

#### Tissue Doppler imaging findings

We did not find any statistical difference in LV peak Sa between MR patients and controls. However, Ea was increased ( $p = 0.0001$ ) and Aa was significantly impaired ( $p = 0.0001$ ) in MR patients. LV E/Ea ratio was also increased in moderate to severe MR patients, supporting the presence of a pseudonormal pattern of LV diastolic dysfunction ( $p = 0.0001$ ). LV Tei index, which is known as a good predictor of both systolic and diastolic functions, was significantly increased in MR patients ( $p = 0.0001$ ), suggesting impairment in LV global functions. Also, the increase in Tei index was significant in MR patients compared to the control group ( $p = 0.0001$ ) (Table II).

In addition, TDI-derived LA  $V_E$  and  $V_A$  were significantly decreased in patients with chronic MR compared to controls ( $p = 0.0001$ ) (Table II).

#### Left atrial function by velocity vector imaging

A total of 1,152 segments were used to identify regional longitudinal function of the LA from apical 4- and 2-chamber views. Because the superior segments' velocity is lower and more difficult to identify, compared to mid and basal segments, we were able to analyse 982 segments over 1,152 segments.

The LA reservoir phase strain was significantly impaired in the MR group, compared to the control ( $p = 0.0001$ ). The LA SRs ( $p = 0.0001$ ), LA ESRd ( $p = 0.0001$ ) and LA LSRd ( $p = 0.0001$ ) were all impaired in patients with moderate to severe MR, when compared to the control group (Table III). There was no significant difference between the strain and strain rates of each segment, suggesting that the LA deformation was global rather than regional.

The LV longitudinal peak systolic strain ( $16.29 \pm 3.30\%$  to  $23.44 \pm 1.90\%$ ;  $p = 0.0001$ ) and SRs ( $0.93 \pm 0.39$  s<sup>-1</sup> to  $4.94 \pm 0.55$  s<sup>-1</sup>;  $p = 0.0001$ ) were also significantly impaired in MR patients, compared to the control group, showing subclinical

**Table II.** Tissue Doppler analyses of the left ventricle and the left atrium

| Parameter        | MR group (n = 48) | Controls (n = 48) | Value of p |
|------------------|-------------------|-------------------|------------|
| LV TDI-Sa [m/s]  | 0.09 ± 0.02       | 0.10 ± 0.11       | 0.18       |
| LV TDI-Ea [m/s]  | 0.13 ± 0.03       | 0.11 ± 0.03       | 0.0001     |
| LV TDI-Aa [m/s]  | 0.10 ± 0.04       | 0.16 ± 0.04       | 0.0001     |
| LV TDI-E/Ea      | 13.0 ± 3.4        | 6.3 ± 3.3         | 0.0001     |
| LV TDI-Tei index | 0.91 ± 0.40       | 0.28 ± 0.06       | 0.0001     |
| LA $V_E$ [m/s]   | 0.11 ± 0.03       | 0.13 ± 0.03       | 0.0001     |
| LA $V_A$ [m/s]   | 0.11 ± 0.05       | 0.16 ± 0.04       | 0.0001     |

LV – left ventricle, TDI – tissue Doppler imaging, Sa – TDI-derived peak systolic velocity, Ea – TDI-derived peak early velocity, Aa – TDI-derived peak atrial velocity, E – peak early velocity, LA  $V_E$  – left atrial early velocity, LA  $V_A$  – left atrial late velocity

**Table III.** Regional longitudinal left atrial functions by velocity vector imaging

| Parameter     | MR group (n = 48) | Control group (n = 48) | Value of p |
|---------------|-------------------|------------------------|------------|
| LA strain (%) | 16.2 ± 8.1        | 51.1 ± 5.7             | 0.0001     |
| LA SRs (1/s)  | 1.01 ± 0.52       | 2.1 ± 0.22             | 0.0001     |
| LA ESRd (1/s) | 0.83 ± 0.34       | 2.26 ± 0.17            | 0.0001     |
| LA LSRd (1/s) | 0.76 ± 0.24       | 2.2 ± 0.26             | 0.0001     |

LA – left atrium, LA SRs – left atrial systolic strain rate, LA ESRd – left atrial early diastolic strain rate, LA LSRd – left atrial late diastolic strain rate

**Table IV.** Comparison of left atrial reservoir deformation indices based on left atrial volume index

| Parameter     | Group I<br>(LAVI ≥ 40 ml/m <sup>2</sup> )<br>(n = 40) | Group II<br>(LAVI < 40 ml/m <sup>2</sup> )<br>(n = 8) | Value of p |
|---------------|---|---|------------|
| LA strain (%) | 13.75 ± 5.6   | 32.2 ± 18.7   | 0.0001     |
| LA SRs (1/s)  | 1.03 ± 0.53   | 2.0 ± 1.2   | 0.003      |

LA – left atrium, LAVI – left atrial volume index, SRs – systolic strain rate

LV systolic dysfunction despite preserved LV EF in chronic MR patients.

Furthermore, we classified the patients according to LAVI into two groups (group I: LAVI ≥ 40 ml/m<sup>2</sup> and group II: LAVI < 40 ml/m<sup>2</sup>) and compared the LA deformation properties to assess the effect of LA volume over LA contractile functions. We found that patients from group I had significantly impaired LA contractile deformation compared to patients from group II (Table IV).

#### Correlation analyses of LA deformation

The correlation analyses of LA deformation indices were analysed. The LA strain was positively correlated with LA ESRd ( $r = 0.834$ ;  $p = 0.0001$ ) and LA LSRd ( $r = 0.842$ ;  $p = 0.0001$ ). The LA strain rate was also positively correlated with LA ESRd ( $r = 0.717$ ;  $p = 0.0001$ ) and LA LSRd ( $r = 0.658$ ;  $p = 0.0001$ ). The LA strain ( $r = 0.747$ ;  $p = 0.0001$ ), and strain rate ( $r = 0.694$ ;  $p = 0.0001$ ) parameters were also positively correlated with LV strain.

The LA ESRd value was negatively correlated with mitral E wave velocity ( $r = -0.371$ ;  $p = 0.003$ ), E/Ea ratio ( $r = -0.292$ ;  $p = 0.02$ ), DT ( $r = -0.410$ ;  $p = 0.0001$ ) and LV Tei index ( $r = -0.537$ ;  $p = 0.0001$ ), suggesting impairment in LV diastolic function. The LA LSRd was negatively correlated with LA RV ( $r = -0.352$ ;  $p = 0.001$ ) and LA VI ( $r = -0.663$ ;  $p = 0.0001$ ).

#### Reproducibility

Intraclass correlations for intra-observer variability were good for VVI-derived parameters (longitudinal strain: 0.85, 95% confidence interval (CI) 0.75-0.98; longitudinal SR: 0.76, 95% CI). The

intraclass correlations for inter-observer variability were also good for VVI-derived measurements (longitudinal strain: 0.88, 95% CI 0.76–0.95; longitudinal SR: 0.87, 95% CI 0.78–0.99).

#### Discussion

In the present study, we found that both the static and dynamic LA volumes are increased in chronic, moderate to severe MR patients. We also detected marked impairment in LA deformation indices, based on VVI-derived strain imaging. The change in the deformation indices were negatively correlated with the corresponding LA volumes. In addition, we demonstrated subclinical LV systolic dysfunction despite preserved LV EF, using strain imaging. Impaired LA deformation indices were significantly correlated with the impairment in LV deformation, showing that LA functions are more deteriorated, associated with the impairment in LV systolic dysfunction.

Chronic MR induces inflammatory changes in the LA myocardium due to progressive volume overload [17]. In previous studies, LA enlargement in patients with chronic MR was reported to be associated with development of atrial fibrillation, need for surgery and increased cardiovascular mortality and morbidity [7, 18–21]. Although conventional echocardiography is widely used to evaluate LA functions, various limitations such as single plane assessment, dependence on LA haemodynamics and image quality deficits exist. For this reason, a gold standard parameter that reflects LA contractility is needed. Quantitative assessment of LA functions using invasive methods is also clinically difficult because of simultaneous LA volume and pressure measuring require-

ments. Tissue Doppler imaging was introduced as an important step towards more reliable and accurate measurements of cardiac regional functions [22–25]. Nevertheless, this method is still problematic due to cardiac rotational motion and tethering effects. Doppler-based strain imaging has emerged as a quantitative technique that estimates myocardial functions and contractility relatively independent of changes in loading, cardiac rotational motion and tethering effects [26, 27]. A limited number of previous studies report that assessment of strain imaging may also be feasible for evaluating LA functions [28–30]. Being one-dimensional and angle dependent, Doppler-based strain imaging has limitations which opened the way for 2-dimensional strain imaging techniques such as speckle tracking and VVI [26–28].

In this study, we used a novel two-dimensional strain imaging (VVI) method for the assessment of LA mechanical changes in patients with chronic moderate to severe MR. In the initial process of MR, LA size and volume increases due to progressive increase in LA volume load. In addition, at early stages or in acutely developed MR, enhancement of LA contractile function may be detected for the preservation of LV stroke volume [3]. As the LA volume overload continues, LA structural changes promote impairment in both LA compliance and contractility.

Passive stretching of the LA wall during LV systole represents LA reservoir function. In the present study, we found a significant increase in reservoir volume in patients with chronic MR due to LA volume overload as expected. Borg *et al.* [14] also demonstrated an increase in LA reservoir volume as well as LA reservoir strain and strain rate in a cohort of patients with chronic moderate to severe MR. They suggested that the increase in LA reservoir function was probably due to increased atrial compliance as a compensatory response to volume overload. In contrast to these results, we found a significant decrease in LA reservoir deformation in our study group, which indicates impairment in LA compliance. This difference may be caused by some clinical differences between the study patients such as the duration of the MR and the amount of volume overload. These two factors are directly responsible for the development of structural changes in the LA wall which cause negative LA remodelling and impairment in LA deformation. In addition, we know that the presence of LV systolic dysfunction may also affect LA reservoir function [29]. In our study, we found marked impairment in LV systolic deformation despite preserved LV EF. Furthermore, impairment in LV systolic deformation was positively correlated with the impairment in LA reservoir deformation.

The conduit phase reflects the passive blood flow from the pulmonary veins down a pressure gradient initiated by LV relaxation. Similar to reservoir volume, conduit volume was also increased in chronic MR patients compared to the healthy controls. We also observed that LA ESRd was significantly decreased in patients with chronic, moderate to severe MR. The ESRd is known as an important determinant of LV early diastolic filling and represents the volume that passes through the LA [30]. We found that impairment in LA ESRd was significantly correlated with the degree of LV diastolic dysfunction. Jarnert *et al.* [8] studied LA deformation using VVI, in order to detect LV diastolic dysfunction in patients with type 2 diabetes mellitus. They demonstrated that LA ESRd was significantly impaired in patients with LV diastolic dysfunction, when compared to the control group. Inaba *et al.* [7] observed that LA ESRd was significantly decreased in patients with paroxysmal and persistent atrial fibrillation.

Atrial contractile function is determined by preload, afterload and LA contractility [17]. In the active contractile phase, the LA contracts and projects blood into the LV in late diastole. In chronic moderate to severe MR, the increase in LV filling pressure causes an increase in atrial afterload and impairment of atrial contraction. In addition, LA contractile function decreases due to fibrosis and other cellular changes in the LA myocardium as a result of LA negative remodelling. In several studies, it has been reported that progressive MR causes a decrease in atrial contractile function [31, 32]. We demonstrated that LSRd of the LA was markedly decreased in chronic MR patients, compared to controls, indicating an impairment in LA contractile function. Furthermore, impairment in LSRd was significantly correlated with surrogates of LA volume overload (LA RV and LAVI). Supporting our results, Shin *et al.* [33] also observed a marked impairment in LA deformation in patients with MR compared to controls. We suggest that, as well as LA negative remodelling, reduced LA contractile deformation may also be due to a combination of enhanced early filling at the expense of late filling, and increased LV diastolic pressures. Cameli *et al.* examined 36 patients with advanced systolic heart failure. They observed a significant negative correlation between LA global longitudinal strain and left ventricular filling pressures, using the speckle tracking method [34]. In a recent study, LA reservoir and contractile function, as well as LA EF, were found to be impaired in patients with chronic MR. They performed their study using the VVI method, similar to our study [35]. In another study performed by Valocik *et al.*, the VVI method was suggested to be a feasible method for the assessment of left atrial volumes and LA EF [36].

Consequently, we suggest that it is important to establish functional changes in LA to give an insight into the pathophysiology of chronic MR. In agreement with previous studies, we found a compensatory increase in LA static and dynamic volumes in patients with primary MR. We also demonstrated that, in advanced disease, serial measurements of LA deformation may detect impairment both in LA and LV compliance and contractile dysfunction. These findings may be useful for deciding the optimal time for mitral valve surgery before irreversible myocardial deterioration develops.

There are very few studies that have analysed the changes in LA mechanical functions in the pathophysiological process of primary MR [13]. The strength of this study is the detailed LA function evaluations by conventional echocardiographic indices accompanied by VVI-derived strain imaging, which may be used in the assessment of subclinical cardiac dysfunction. The major limitation of our study is that we were not able to perform coronary angiography in all of our patients. Only 25 MR patients had an angiogram with normal coronary arteries. Fifteen patients had negative exercise stress testing. The rest of the study patients had no clinical features of CAD. In addition, we did not find any regional deformation in the study group. Therefore, we assume that none of the patients had ventricular dysfunction due to CAD. It is obvious that the LA is a chamber which is susceptible to volume and pressure changes such as preload and afterload alterations. For this reason, the significant differences between the patients and the healthy controls, regarding volume and deformation indices, are expected results of this study. Another limitation is that we were not able to compare our results with a gold standard method for the evaluation of LA function. Further studies are needed to determine the efficiency of VVI imaging modality on atrial functions.

## References

1. Avierinos JF, Gersh BJ, Melton LJ III, et al. Natural history of asymptomatic mitral valve prolapse in the community. *Circulation* 2002; 106: 1355-61.
2. Grigioni F, Avierinos JF, Ling LH, et al. Atrial fibrillation complicating the course of degenerative mitral regurgitation: determinants and long-term outcome. *J Am Coll Cardiol* 2002; 40: 84-92.
3. Boudoulas KD, Sparks EA, Rittgers SE, Wooley CF, Boudoulas H. Factors determining left atrial kinetic energy in patients with chronic mitral valve disease. *Herz* 2003; 28: 437-44.
4. Boudoulas H, Boudoulas D, Sparks EA, Pearson AC, Nagaraja HN, Wooley CF. Left atrial performance indices in chronic mitral valve disease. *J Heart Valve Dis* 1995; 4: S242-7.
5. Benedetto U, Melina G, Roscitano A, Ciavarella GM, Tonelli E, Sinatra R. Clinical utility of tissue Doppler imaging in prediction of AF after coronary artery bypass grafting. *Ann Thorac Surg* 2007; 83: 83-8.
6. Vogel M, Schmidt MR, Kristiansen SB, et al. Validation of the myocardial acceleration during isovolumic contraction as a novel index of right ventricular contractility. *Circulation* 2002; 105: 1693-9.
7. Inaba Y, Yuda S, Kobayashi N, et al. Strain rate imaging for noninvasive functional quantification of the left atrium: comparative studies in controls and patients with AF. *J Am Soc Echocardiogr* 2005; 18: 729-36.
8. Jarnert C, Melcher A, Caidahl K, Persson H, Rydén L, Eriksson MJ. Left atrial velocity vector imaging for the detection and quantification of left ventricular diastolic function in type 2 diabetes. *Eur J Heart Fail* 2008; 10: 1080-7.
9. Tayyareci Y, Yildirimturk O, AYTEKİN V, Demiroglu ICC, AYTEKİN S. Subclinical left ventricular dysfunction in asymptomatic severe aortic regurgitation patients with normal ejection fraction: a combined tissue Doppler and velocity vector imaging based study. *Echocardiography* 2010; 27: 260-8.
10. Feigenbaum H, Armstrong WF, Ayan T. Feigenbaum's Echocardiography. 6<sup>th</sup> ed. Lippincotts Williams & Wilkins 2005; 355-6.
11. Lester SJ, Ryan EW, Schiller NB, Foster E. Best method in clinical practice and in search studies to determine left atrial size. *Am J Cardiol* 1999; 84: 829-32.
12. Zoghbi WA, Enriquez-Sarano M, Fopster E, et al. American Society of Echocardiography. Recommendations for evaluation of the severity of native valvular regurgitation with two-dimensional and Doppler echocardiography. *J Am Soc Echocardiogr* 2003; 16: 777-802.
13. Dujardin KS, Enriquez-Sarano M, Bailey KR, Nishimura RA, Seward JB, Tajik AJ. Grading of mitral regurgitation by quantitative Doppler echocardiography: calibration by left ventricular angiography in routine clinical practice. *Circulation* 1997; 96: 3409-15.
14. Borg AN, Pearce KA, Williams SG, Ray SG. Left atrial function and deformation in chronic primary mitral regurgitation. *Eur J Echocardiogr* 2009; 10: 833-40.
15. Feigenbaum H, Armstrong WF, Ayan T. Feigenbaum's Echocardiography. 6<sup>th</sup> ed. Lippincotts Williams & Wilkins 2005; 221-2.
16. Brennan SA. Statistical methods for assessing observer variability in clinical measures. *BMJ* 1992; 304: 1491-9.
17. Thiedemann KU, Ferrans VJ. Left atrial ultrastructure in mitral valvular disease. *Am J Pathol* 1977; 89: 575-604.
18. Vaziri SM, Larson MG, Lauer MS, Benjamin EJ, Levy D. Influence of blood pressure on left atrial size. The Framingham Heart Study. *Hypertension* 1995; 25: 1155-60.
19. Reed D, Abbott R, Smucker M, Kaul S. Prediction of outcome after mitral valve replacement in patients with symptomatic chronic mitral regurgitation. The importance of left atrial size. *Circulation* 1991; 84: 23-34.
20. Ling H, Enriquez-Sarano M, Seward T, et al. Clinical outcome of mitral regurgitation due to flail leaflets. *N Engl J Med* 1996; 335: 1417-23.
21. Benjamin EJ, D'Agostino RB, Belanger AJ, Wolf PA, Levy D. Left atrial size and the risk of stroke and death. The Framingham Heart Study. *Circulation* 1995; 92: 835-41.
22. Thomas L, Lewett K, Boyd A, Leung YC, Schiller NB, Ross DL. Changes in regional left atrial function with aging: evaluation by Doppler tissue imaging. *Eur J Echocardiogr* 2003; 4: 92-100.
23. Hattle L, Sutherland GR. Regional myocardial function: a new approach. *Eur Heart J* 2000; 21: 1337-57.
24. Wilinski J, Czarnecka D, Wojciechowska W, et al. Baseline tissue Doppler imaging-derived echocardiographic



- parameters and left ventricle reverse remodelling following cardiac resynchronization therapy introduction. *Arch Med Sci* 2011; 7: 813-22.
25. Shen X, Aronov WS, Anand K, et al. Evaluation of left ventricular dyssynchrony using combined pulsed wave and tissue Doppler imaging. *Arch Med Sci* 2010; 6: 519-25.
  26. Serri K, Reant P, Lafitte M, et al. Global and regional myocardial function quantification by two-dimensional strain. *J Am Coll Cardiol* 2006; 47: 1175-81.
  27. Chen J, Cao T, Duan T, Yuan L, Yang Y. Velocity vector imaging in assessing the regional systolic function of patients with post myocardial infarction. *Echocardiography* 2007; 24: 940-5.
  28. Modesto KM, Cauduro S, Dispenzieri A, et al. Two-dimensional acoustic pattern derived strain parameters closely correlate with one-dimensional tissue Doppler derived strain measurements. *Eur J Echocardiogr* 2006; 7: 315-21.
  29. Barbier P, Solomon SB, Schiller NB, Glantz SA. Left atrial relaxation and left ventricular systolic function determine left atrial reservoir function. *Circulation* 1999; 100: 427-36.
  30. Wang T, Wang M, Fung JW, et al. Atrial strain rate echocardiography can predict success or failure of cardioversion for atrial fibrillation: a combined transthoracic tissue Doppler and transesophageal imaging study. *Int J Cardiol* 2007; 114: 202-9.
  31. Payne RM, Stone HL, Engelken EJ. Atrial function during volume loading. *J Appl Physiol* 1971; 31: 326-31.
  32. Sadaniantz A, Miller G, Hadi BJ, Parisi AF. Effects of left ventricular systolic function on left ventricular diastolic filling patterns in severe mitral regurgitation. *Am J Cardiol* 1997; 79: 1488-92.
  33. Shin MS, Kim BR, Oh KJ, et al. Echocardiographic assessment of left atrial strain and volume in healthy patients and patients with mitral valvular heart disease by tissue Doppler imaging and 3 dimensional echocardiography. *Korean Circ J* 2009; 39: 280-90.
  34. Cameli M, Lisi M, Mondillo S, et al. Left atrial longitudinal strain by speckle tracking echocardiography correlates well with left ventricular filling pressures in patients with heart failure. *Cardiovascular Ultrasound* 2010; 8: 14.
  35. Moustafa SE, Alharthi M, Kansal M, Deng Y, Chandrasekaran K, Mookadam F. Global left atrial dysfunction and regional heterogeneity in primary chronic mitral insufficiency. *Eur J Echocardiogr* 2011; 12: 384-93.
  36. Valocik G, Druzbacka L, Valocikova I, Mitro P. Velocity vector imaging to quantify left atrial function. *Int J Cardiovasc Imaging* 2010; 26: 641-9.