

Emergency surgical approach to device emboli due to migration of the atrial septal defect occluder

Ufuk Yetkin¹, Ismail Yurekli¹, Zehra Ilke Akyildiz², Orhan Gokalp¹, Omer Tetik³, Banu Lafci¹, Oktay Ergene², Ali Gurbuz¹

¹Department of Cardiovascular Surgery, Izmir Ataturk Education and Research Hospital, Izmir, Turkey

²Department of Cardiology, Izmir Ataturk Education and Research Hospital, Izmir, Turkey

³Department of Cardiovascular Surgery, Bursa Yuksek Ihtisas Hospital, Bursa, Turkey

Submitted: 5 April 2012

Accepted: 18 July 2012

Arch Med Sci 2014; 10, 3: 464–469

DOI: 10.5114/aoms.2014.43741

Copyright © 2014 Termedia & Banach

Corresponding author:

Ismail Yurekli

Department of Cardiology

Izmir Ataturk Education

and Research Hospital

6436 sok 82/3

35540 Karsiyaka-Izmir,

Turkey

Phone: +90(505)5251202

Fax: +90(232)2431530

E-mail: ismoyurekli@yahoo.

com

Abstract

Introduction: Atrial septal defect (ASD) transcatheter occlusion techniques are now established as the preferred method and have become an alternative to surgery under extracorporeal circulation. In this study, we aimed to present our emergency surgical approach to cases of device embolization due to migration of the atrial septal defect occluder.

Material and methods: Between June 2009 and June 2011, 6 patients underwent emergency operations due to device emboli secondary to migration of the transcatheter atrial septal defect occluder during the early period. Mean age was 25.5 years (15–45) and 3 of the patients were female (50%). The diagnosis was made via transthoracic echocardiography (TTE) preoperatively.

Results: All of these 6 patients underwent emergency operations. Mean postoperative intensive care unit (ICU) stay was 2.2 days and mean hospital stay was 6 days. No early or late postoperative mortality was seen. Mean postoperative follow-up time was 19.3 months (range: 5–28 months). Early- and late-period TTE examinations showed no residual interatrial shunting. One patient developed a right atrial thrombus in the postoperative 22nd month as a complication of long-term follow-up. He was treated with anticoagulant therapy for 6 months with complete resolution at the TTE.

Conclusions: Transcatheter occlusion of secundum type ASD provides prominent clinical improvement, as well as a regression in dimensions of cardiac chambers. Nevertheless, this technique has drawbacks such as distal migration and residual shunts. Consequently, we think that unfavorable anatomy and device diameter are major issues in device migration. Oversizing also increases the migration risk.

Key words: Amplatzer septal occluder, embolization, migration, secundum type atrial septal defect.

Introduction

The secundum type atrial septal defect (ASD) is the fourth most common congenital heart defect, with an incidence of 3.78 per 10,000 live births [1, 2], corresponding to 5.9% of cases of diagnosed congenital heart disease in children [3]. In the last 50 years cardiac catheterization has changed its primary role from a diagnostic investigation to that

Table I. Demographic data and preoperative characteristics of our patients

Patient no.	Age [year]	Gender	Brand name of the device and sizing measurements	Deployment-to-diagnosis of migration time
1	45	♂	Cardiofix; 35 mm	10 min (under fluoroscopy)
2	15	♀	Biostar; occluder; 16 mm	6 h
3	18	♂	Amplatzer ASD; occluder; 30 mm	48 h (control x-ray – Figure 1)
4	19	♂	Amplatzer ASD; occluder; 31 mm	24 h
5	40	♀	Amplatzer ASD; occluder (another institution)	14 days
6	16	♀	Amplatzer ASD; occluder; 34 mm	12 h

of a therapeutic procedure [4]. William Rashkind pioneered percutaneous closure of ASD. The first application in humans was done in 1974 by Jim Lock and was published in 1976 [5]. Percutaneous ASD closure has become an increasingly simplified procedure over the past decade [1]. The use of dedicated devices for ASD closure by experienced operators results in low rates of device dislodgement, migration or embolization and improves sealing performance [4, 6]. A cause of failure is early embolization [7]. The percentage of this early embolization is around 0.5% [3].

In this study, we aimed to present our emergency surgical approach to cases with device emboli due to migration of the atrial septal defect occluder diagnosed during the early period after implantation.

Material and methods

Between June 2009 and June 2011, 6 patients underwent emergency operations due to device emboli secondary to migration of the transcatheter atrial septal defect occluder during the early period. Five of these patients underwent transcatheter closure at the Cardiology Department

of our institution, whereas the remaining patient underwent this procedure in another institution. All of these patients were referred to our clinic for emergency surgery. Mean age was 25.5 years (15–45) and 3 of the patients were female (50%). Timing of the emergency operation was planned after the diagnosis of the migration of the occluder in 10 min to 2 weeks after the intervention. The demographic data and the device characteristics are summarized in Table I (The 5th patient was referred from another institution. Therefore, the sizing measurements were not available.) The diagnosis was made via transthoracic echocardiography (TTE) preoperatively. The migration of the device was noticed during fluoroscopy in the 10th min after the deployment in the 1st case. In the 3rd case, this displacement was detected at control chest X-ray in the 48th h after the deployment (Figures 1 and 2). In the 1st case, the operating team of the Cardiology Department tried to remove the embolized device from the right ventricle with biopsy forceps; but this attempt was unsuccessful. The remaining 5 patients were directly referred to our clinic for surgery. All 6 patients underwent emergency operations. The operation technique was standard with inclusion of pulmonary arteriotomy in cases of migration to the pulmonary artery. After median sternotomy, the pericardium was incised vertically. Following the standard bi-

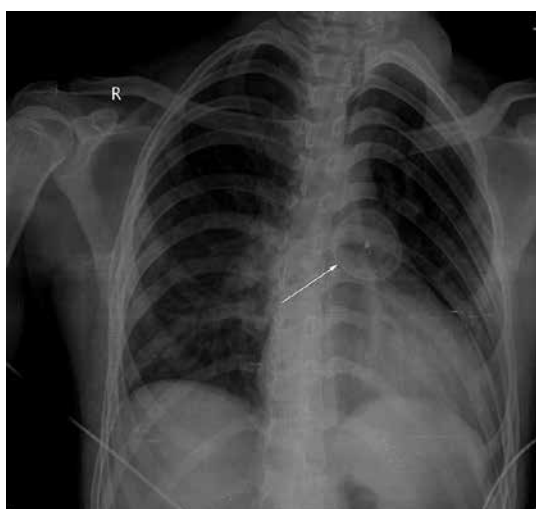

Figure 1. Chest X-ray view of our 3rd patient showing the embolized device in the pulmonary conus

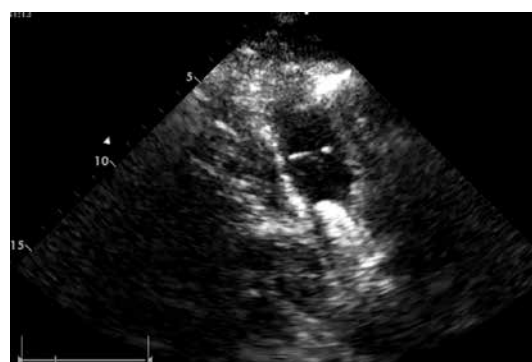

Figure 2. TTE view of our 4th patient showing migration of the Amplatzer occluder device into the main pulmonary artery 24 h after its deployment

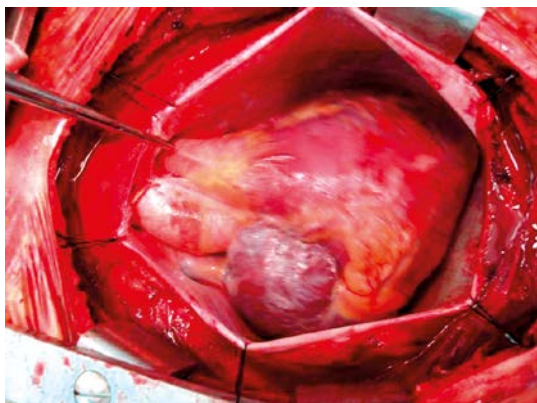


Figure 3. Perioperative view after median sternotomy showing embolized Amplatzer occluder device within main pulmonary artery

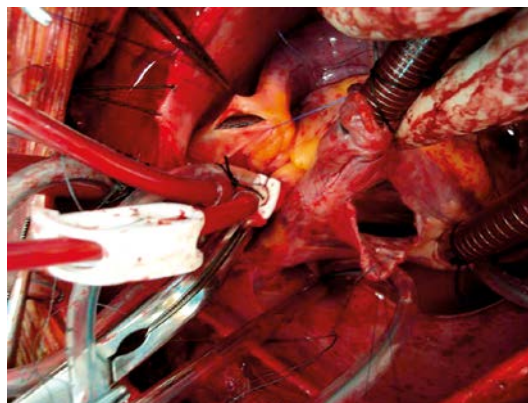


Figure 4. Simultaneous perioperative views of the embolized device after pulmonary arteriotomy and fossa ovalis type secundum ASD after right atriotomy

caval cannulation and aortic cross-clamping, antegrade tepid blood cardioplegia was introduced. Standard right atriotomy was performed in all cases. Four patients (cases no. 3–6) underwent vertical pulmonary arteriotomy to identify the devices in the main pulmonary artery (Figures 3 and 4). In these 4 cases, primary closure of atrial septal defect was carried out after removal of the device. The diameter of these 4 devices reached up to 50 mm after migration into pulmonary arteries. Mean aortic cross-clamp time was 27.6 min (range: 18–34 min). Mean cardiopulmonary bypass time was 48.5 min (range: 39–54 min). These periods were longer in cases requiring pulmonary arteriotomy (Table II).

Results

Perioperative data

The location of the embolized device was the main pulmonary artery in 3 cases, the right ventricular outflow tract in one case, the right atrial cavity in one case and right pulmonary artery inflow in the remaining case. Four of our patients required pulmonary arteriotomy. The type of ASD was detected as fossa ovalis type in 4 patients during surgical exploration. One patient had a si-

nus venosus type defect, whereas the remaining 1 had a patent foramen ovale. All these defects were closed primarily by simple suturing.

Early postoperative period

The postoperative course was uneventful for all patients. The length of postoperative intensive care unit (ICU) stay was 2 days in 5 patients and 1 day in the remaining one. The length of postoperative hospital stay was 6 days in 3 patients, 5 days in 2 patients and 8 days in 1 patient. The amount of whole blood transfusion was 1 unit in 5 patients and none in the remaining one. The amount of packed red blood cells transfused was 1 unit in 1 patient and 2 units in 5 patients. The amount of fresh frozen plasma (FFP) was 3 units in 1 patient, 1 unit in 4 patients and none in 1 patient.

No early or late postoperative mortality was seen. In addition, no arrhythmia – particularly supraventricular tachycardia requiring electrical or medical cardioversion – was seen. There were also no pericardial effusion, procedure-related vascular access complications, peripheral embolization, transient ST elevation, infectious endocarditis, deep venous thrombosis or surgical re-exploration due to bleeding. The mean amount of postoper-

Table II. Aortic cross clamp time, cardiopulmonary bypass time, amount of postoperative mediastinal drainage of the patients

Patient no.	Aortic cross clamp time [min]	Cardiopulmonary bypass time [min]	Amount of postoperative mediastinal drainage [cc]
1	28	48	350
2	18	39	200
3	34	54	1350
4	33	51	400
5	28	51	350
6	25	47	450

ative mediastinal drainage was 516.6 ml (range: 200–1350 ml). This amount was higher in patients requiring pulmonary arteriotomy (Table II).

Postoperative follow-up

All the patients returned for a regular check-up visit at 1, 3, 6 and 12 months after the operation and yearly thereafter with clinical and TTE examinations at each visit. The mean postoperative follow-up period was 19.3 months (range: 5–28 months). Early- and late-period transthoracic echocardiography confirmed that there was no residual shunting in the interatrial septum. As a late-period postoperative complication, one patient had a hyperechoic mobile intracardiac mass of 30 mm × 16 mm consistent with thrombus which was detected with TTE in the 22nd month. He was suffering from chest pain and shortness of breath. This pedunculated mass was located within the right atrium (Figure 5). In addition, the diameter of the main pulmonary artery was measured as 25 mm and no thrombus was detected inside it and its branches. Our patient was immediately hospitalized in the intensive care unit and anticoagulated with an intravenous infusion of standard heparin, keeping the activated clotting time at 220 ±20 s. On the 3rd day of hospitalization, he was transferred to the ward. Whole abdominal ultrasound and venous Doppler ultrasound of both lower extremities showed no additional pathology. Concomitant warfarin therapy was also initiated, keeping the international normalized ratio (INR) level at a level of 2.4 ±0.2. Genetic analyses regarding Factor V Leiden mutation, prothrombin 20210 mutation, MTHFR 677 gene polymorphism, antithrombin III activity, homocysteine level, and protein C and S deficiency revealed heterozygous mutation of Factor V. On the 7th postoperative day, he achieved a full symptomatic recovery. Control TTE investigation showed regression of the size of the right atrial thrombus material down to 21.6 mm × 14.7 mm. Outpatient follow-up with oral anticoagulation therapy was recommended by the Hematology Department. He was treated with anticoagulant therapy for 6 months with complete resolution at the TTE. Preoperative pulmonary arterial pressure (PAP) of 100 mm Hg showed regression down to 45 mm Hg at the end of a 2-year follow-up period in patient 1. The PAP of patient 5 was measured as 35–40 mm Hg. Beside these 2 patients, the PAP values were measured as below 30 mm Hg. At the end of the postoperative 6th month, the PAP values were within normal limits except for patient 1 as measured with TTE. In addition, no moderate or severe tricuspid regurgitation was detected pre- or postoperatively.

Discussion

Until now, surgical closure of the defect was the only treatment recommended and good results were observed [7]. Most recently, ASD transcatheter occlusion techniques have become an alternative to surgical procedure using cardiopulmonary bypass [1]. Transcatheter closure of ASD has better results than medical therapy and comparable results to surgical closure, thus avoiding the even low morbidity and mortality rates of surgery for such congenital heart disease in adults [8–10]. Transcatheter closure of ASD avoids sternotomy and extracorporeal circulation and it is performed under local anesthesia under fluoroscopic guidance in a very short time with experience gained, and with very low radiation exposure [7, 11].

A number of different devices are available for transcatheter ASD closure [1]. The Amplatzer ASD occluder was used in our four cases. Three of these devices embolized to the main pulmonary artery and one to the inlet of the right pulmonary artery. It was constructed from nitinol wires and consisted of two flat disks with a 3-mm long thin connecting waist. The Amplatzer device became the first choice for closing defects larger than 18 mm [1].

The implanted device should allow complete closure with no residual shunt and also should be biocompatible, with no allergenic or traumatic components, easy to implant and to immediately retrieve in case of malposition [4]. It is important to document all subsequent complications to properly evaluate the benefit/risk ratio of a percutaneous ASD closure and to choose the appropriate device.

Embolization of the device remains one of the possible complications. Devices usually embolize into the main pulmonary artery [1]. This rate of embolization was 89% in the study of Chessa *et al.* and they embolized within 24 h. In our series the rate of embolization in the main pulmonary artery is 67% (4 cases). Again in our series, embo-

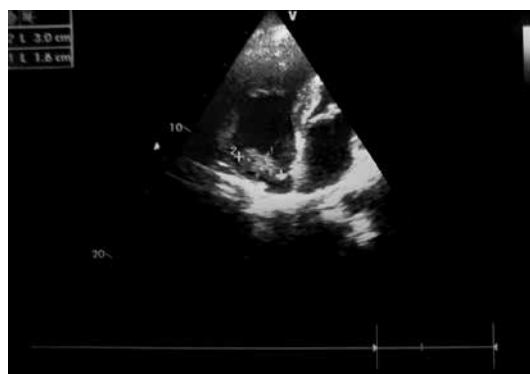

Figure 5. TTE view of one of our patients showing hypoechoic mobile mass lesion of 30 mm × 16 mm inside the right atrium consistent with thrombus material and successful closure of ASD

lization due to migration was detected within the first 24 h except for the 3rd and 5th patient (67%, Table I). Once the device embolizes, two different options are possible (1): i) retrieve the device by a gooseneck snare or basket catheter, ii) refer the patient to the surgeon. The last option is indicated when the size of the device is among the largest; the surgeon retrieves the device and closes the ASD at the same time. In our series, 5 patients were taken to the operating room for emergency surgery. The remaining case was subjected to an unsuccessful attempt of retrieval under fluoroscopy by cardiologists due to migration of the device 10 min after its deployment.

Transthoracic echocardiography can confirm the suspected diagnosis [4]. Although the migration of the device was confirmed by TTE examination in all our patients, the diagnosis was made under fluoroscopy in 1 patient 10 min after deployment of the device and coincidentally in another patient in routine control chest X-ray examination, interestingly (Figure 1). Surgery usually follows: the device is retrieved and the septum sutured [4].

Other serious complications that occur in less than 1% of cases are infection, erosion into the pericardium or aorta at the rim of the device, a new ASD caused by the tearing of the thin septum primum by the lower rim, atrial fibrillation, and palpitations, which are not common and usually subside spontaneously [6, 12]. Reporting those complicated cases should help improve the understanding of such complications, their risk factors, the delay of occurrence, the selection of patients, the implantation techniques and the design of the devices, and refine the adjuvant medical treatment [4].

The relationship between the device and the peripheral tissue of the atrial septal defect must be delineated, and the smallest possible device must be used [7]. To reduce the risk of such mechanical complications, one needs to keep in mind the risk factors previously described. In the near future, less aggressive techniques (radiofrequency closure system) or even bioabsorbable devices may be available [4].

Development of right atrial thrombus in the long term after primary repair of ASD is extremely rare. It carries a potential for embolic sequelae and is therefore important [13]. In this case, second surgical intervention, thrombolysis and anticoagulation are alternative approaches. Whatever the treatment modality the clinician chooses regarding the patient's condition, he/she should take into consideration the fact that a fast and aggressive approach has a positive impact on survival. This complication was seen in 1 of our patients. We treated him with a combination of sys-

temic heparinization followed by oral anticoagulant therapy for 6 months.

In conclusion, this study had some limitations. It involved a small number of patients and also the follow-up period was not long enough. Transcatheter closure of ASD is safe, gives better results and has become an alternative to surgery under extracorporeal circulation. Marked progress in interventional cardiology has led to the development of a non-surgical method for secundum ASD (ASD II) treatment, and percutaneous closure of single ASD II has become the standard treatment, possible in about 60–70% of patients depending on the defect location, size and patient's age [2]. The key to success of every miniinvasive hybrid approach is perfect cooperation of interventional cardiologists, surgeons and anesthesiologists [14]. One should be aware that transcatheter closure has some complications as seen in our series: migration to the chambers of the right heart, and development of residual interatrial shunting. As a consequence derived from our study, the operators of this intervention should keep in mind that unfavorable anatomy and the device diameter are major issues in device migration. Oversizing also increases the migration risk. There are several technical limitations, such as diameters of the occluder and delivery system, that need to be considered before implantation [14]. The contraindications for percutaneous closure include a large defect or too small surrounding rims (except for the anterior rim toward the aorta) [2].

References

1. Chessa M, Carminati M, Butera G, et al. Early and late complications associated with transcatheter occlusion of secundum atrial septal defect. *J Am Coll Cardiol* 2002; 39: 1061-5.
2. Kucinska B, Werner B, Wroblewska-Kaluzewska M. Assessment of right atrial and right ventricular size in children after percutaneous closure of secundum atrial septal defect with Amplatzer septal occluder. *Arch Med Sci* 2010; 6: 567-72.
3. Ueda H, Yanagi S, Nakamura H, et al. Device closure of atrial septal defect: immediate and mid-term results. *Circ J* 2012; 76: 1229-34.
4. Motreff P, Dauphin C, Souteyrand G. Cardiac perforation and tamponade 3 months after transcatheter PFO closure by Starflex Device: a case report. *Cathet Cardiovasc Interv* 2008; 71: 412-6.
5. King TD, Thompson SL, Steiner C, et al. Secundum atrial septal defect. Nonoperative closure during cardiac catheterization. *JAMA* 1976; 235: 2056-9.
6. Meier B. Closure of patent foramen ovale: technique, pitfalls, complications, and follow up. *Heart* 2005; 91: 444-8.
7. Guérin P, Lambert V, Godart F, et al. Transcatheter closure of patent foramen ovale in patients with platypnea-orthodeoxia: results of a multicentric French registry. *Cardiovasc Intervent Radiol* 2005; 28: 164-8.

8. Rigatelli G, Cardaioli P, Giordan M, et al. Transcatheter intracardiac echocardiography-assisted closure of interatrial shunts: complications and midterm follow-up. *Echocardiography* 2009; 26: 196-202.
9. Post MC, Suttorp MJ, Jaarsma W, et al. Comparison of outcome and complications using different types of devices for percutaneous closure of a secundum atrial septal defect in adults: a single-center experience. *Catheter Cardiovasc Interv* 2006; 67: 438-43.
10. Vida VL, Berggren H, Brawn WJ, et al. Risk of surgery for congenital heart disease in the adult: a multicentered European study. *Ann Thorac Surg* 2007; 83: 161-8.
11. Godart F, Rey C, Prat A, et al. Atrial right-to-left shunting causing severe hypoxemia despite normal right-sided pressures. Report of 11 consecutive cases corrected by percutaneous closure. *Eur Heart J* 2000; 21:483-9.
12. Yoon JH, Kim JS, Lee DH, et al. Intermediate and long-term results of transcatheter closure of patent foramen ovale using the Amplatzer patent foramen ovale occluder: one case of pulmonary embolism irrespective of patent foramen ovale closure. *Korean Circ J* 2011; 41: 356-62.
13. Sheikh AY, Schrepfer S, Stein W, et al. Right atrial mass after primary repair of an atrial septal defect: thrombus masquerading as a myxoma. *Ann Thorac Surg* 2007; 84: 1742-4.
14. Haponiuk I, Chojnicki M, Jaworski R, et al. Miniinvasive hybrid closure of multiple muscular ventricular septal defects in a premature infant with novel use of Amplatzer Duct Occluder II-a case report. *Videosurg Miniinv* 2011; 6: 33-6.