

Color Doppler dynamic tissue perfusion measurement: a novel tool in the assessment of renal parenchymal perfusion in children with vesicoureteral reflux

Magdalena M. Woźniak¹, Thomas M. Scholbach², Jakob Scholbach³, Agata Pawelec¹, Paweł Nachulewicz⁴, Andrzej P. Wieczorek¹, Agnieszka Brodzisz¹, Maria M. Zajączkowska⁵, Halina Borzęcka⁵

¹Department of Pediatric Radiology, Medical University of Lublin, Lublin, Poland

²Hospital for Children and Adolescents, Chemnitz Clinics, Chemnitz, Germany

³University of Münster, Münster, Germany

⁴Department of Pediatric Surgery and Traumatology, Medical University of Lublin, Lublin, Poland

⁵Department of Pediatric Nephrology, Medical University of Lublin, Lublin, Poland

Submitted: 22 July 2014

Accepted: 25 November 2014

Arch Med Sci 2016; 12, 3: 621–628

DOI: 10.5114/aoms.2015.51698

Copyright © 2016 Termedia & Banach

Corresponding author:

Magdalena M. Woźniak
Department of Pediatric
Radiology
Medical University of Lublin
Al. Ractawickie 1
20-059 Lublin, Poland
Phone: +48 817418447
Fax: +48 817418447
E-mail: mwozniak@hoga.pl

Abstract

Introduction: Vesicoureteral reflux (VUR) occurs in 20–50% of children suffering from recurrent urinary tract infections (UTIs) and is associated with an increased risk of renal scarring and impaired renal function. Early detection of renal perfusion deterioration would allow for the implementation of more aggressive treatment and potentially prevent further damage to the renal parenchyma. The aim of the study was to assess renal parenchymal perfusions in children with recurrent UTIs with and without coexisting VUR, and compare the findings with the results of healthy patients.

Material and methods: Color Doppler sonographic dynamic renal parenchymal perfusion measurements were performed with PixelFlux (Chameleon-Software, Germany) software in 77 children with recurrent UTIs and coexisting VUR and in 30 children with UTIs without VUR. The findings were compared with the results of 53 healthy children.

Results: Cortical parenchymal perfusion of children suffering from UTIs and VUR was significantly reduced when compared to the control group. Statistically significant differences ($p < 0.05$) were found in all perfusion parameters (i.e. mean velocity (v_{mix}), mean perfused area (A_{mix}), mean perfusion intensity (I_{mix}), tissue pulsatility index (TPI), and tissue resistance index (TRI)) between the control group and children suffering from UTIs and VUR, particularly VUR grades III and IV. There were no significant differences between the UTI group and the control group. No differences were found between the controls and VUR grade II.

Conclusions: Renal parenchymal perfusion decreases significantly with higher grades of VUR.

Key words: renal parenchymal perfusion, urinary tract infections, vesicoureteral reflux, PixelFlux.

Introduction

Vesicoureteral reflux (VUR) is present in approximately 1% of children in Europe and North America, and has a frequency of 20% to 50% in

children suffering from recurrent urinary tract infections (UTIs) [1]. Higher grades of VUR, recurrent febrile UTI, and older age are associated with an increased risk of pyelonephritis, renal scarring, and, consequently, impaired renal function [2, 3]. Diagnosis of renal scarring includes ultrasonography with the use of B-mode and color/power Doppler modes, intravenous urography, technetium-99m dimercaptosuccinic acid (DMSA) scintigraphy, and magnetic resonance imaging (MRI) [4, 5]. In all of the mentioned imaging techniques, relatively advanced stages of renal scarring can be detected when there is profound and substantial morphological deterioration in the renal parenchyma. However, earlier detection of a decline in renal perfusion would allow for the implementation of more aggressive treatment and potentially prevent further damage to the renal parenchyma. Moreover, current techniques are costly, use radiating substances, or have relatively limited availability. Therefore, a new technique to evaluate the state of the renal parenchyma is needed. Moreover, this procedure should allow for the detection of functional restriction of the renal cortex before scarring manifests. Localized scarring is only one risk in VUR. Another is diffused fibrosis of the parenchyma with a shrinking cortex and renal growth restriction in childhood. The impending morphological damage is preceded by a decline in renal cortical perfusion. Simple, non-invasive color Doppler sonographic dynamic tissue perfusion measurements using PixelFlux software (Chameleon Software, Germany) have been previously reported as a reliable tool for the assessment of perfusion in the kidneys, kidney transplants, urethra, and other organs [6–11]. The software provides a simple process for the quantification of perfusion parameters and may be a useful diagnostic tool for the evaluation of renal parenchymal perfusion in children suffering from UTIs.

In the current study, color Doppler sonographic dynamic tissue perfusion measurement (DTPM) was used to evaluate renal parenchymal perfusion in children with recurrent UTIs with and without coexisting VUR, and the results were compared with those obtained in healthy age-matched subjects.

Material and methods

Patients

The study group included 107 consecutive children (mean age \pm SD 3.9 \pm 3.5 years, range 1 month to 15.7 years; mean body mass index (BMI) 18.1 kg/m², range 16.6–21.4 kg/m²) suffering from recurrent UTIs with no obvious scars on renal ultrasound or scintigraphy. The group was

divided into two subgroups: study group 1 included those with coexisting VUR (77 children), and study group 2 included those without coexisting VUR (30 children). In study group 1 (with VUR), 25 patients suffered from bilateral and 52 from unilateral reflux. Only the kidneys with VUR (102 kidneys) were included in the analysis and were further analyzed according to VUR grade. For patients in study group 2 (with UTIs without VUR), the analysis included data from both kidneys (60 kidneys). VUR had previously been diagnosed or excluded with contrast-enhanced voiding urosonography (ce-VUS) performed by the standard protocol used in our center [12]. Recurrent UTIs were diagnosed based on clinical symptoms, and positive urine analysis and culture. Apart from renal scarring, the exclusion criteria included any coexisting congenital abnormalities of the urogenital tract, in particular the ureterocele, ectopic ureters, posterior urethral valves, or neurogenic bladder. All children were scanned at least four weeks after the last UTI episode.

Among the 77 children suffering from recurrent UTIs and VUR (study group 1), there were no children with VUR grade I. Among consecutive patients, there were only three children with unilateral VUR grade I who were excluded from the study based on the small group size, which was not appropriate for the statistical analysis. The seven children with VUR grade V had previously been excluded from the study (since either renal scarring was diagnosed or they suffered from congenital abnormalities of the urogenital tract, or they had both conditions). Therefore, study group 1 included only patients with VUR grades II, III, and IV who met the inclusion criteria.

Control group

The control group included 53 healthy children (mean \pm SD 5.4 \pm 4.6 years, range 4 months to 17.9 years; mean: BMI 18.5 kg/m², range: 16.4–22.2 kg/m²) without a history of renal disease or acute nephritis (based on clinical and laboratory data), and with normal renal ultrasound. Patients had been referred for abdominal ultrasound examination to clarify abdominal discomfort or pain, and only those with no diagnosed abnormalities were included in the control group.

Color Doppler ultrasonography

Color Doppler sonographic investigations of the kidneys were performed using a Micro Convex 3–9 MHz transducer and a Voluson E8 ultrasound scanner (GE Healthcare, USA). The examinations were performed with a fixed algorithm and predefined machine settings in all patients and controls. The ultrasound machine settings were stan-

standardized as follows: a 7 MHz harmonic B-mode frequency, 9 cm/s maximum color coded velocity, low frequency, low to normal quality, wall motion filter (WMF), 3 speckle reduction imaging (SRI) II, and 0.9 kHz pulse repetition frequency (PRF). To avoid aliasing, color flow velocity settings were changed if necessary. A video sequence of 2 s was recorded, and each contained at least one full heart cycle. All examinations were performed by one investigator experienced in pediatric ultrasonography. Standardized recordings of color Doppler sonographic videos in the DICOM format were transferred to a personal computer. Subsequently, dynamic color Doppler tissue perfusion measurements (DTPMs) were carried out using the PixelFlux software (Chameleon-Software, Germany) by another investigator blinded to which group the patients belonged.

Dynamic color Doppler tissue perfusion measurement

In this study, the following parameters were automatically computed for each single frame of the video within each region of interest (ROI):

- the mean velocity (v), which corresponds to the color hue of the pixels inside the ROI;
- the mean perfused area (A), which is given by the number of perfused pixels inside the ROI;
- the perfusion intensity (I), which is defined as the ratio: $I [\text{cm/s}] = v [\text{cm/s}] \times A [\text{cm}^2] / A_{ROI} [\text{cm}^2]$, where A_{ROI} denotes the total area of the ROI. In this way, the perfusion intensity increases with the perfusion velocity, but decreases if less of the total ROI area is perfused.

The perfusion intensity is calculated for every image in each video in order to compute averages and pulsation indices of the parameters with respect to the duration of a full cardiac cycle. The whole area occupied by the colored pixels inside the ROI is calculated. This calculation is automatically repeated for the same ROIs for all images of a digital video. In addition to the measurement of flow quantity inside the ROI, which is known as ‘perfusion intensity’ (I) [7, 13], the other parameters that were calculated to describe the perfusion within the entire ROI include:

- the tissue pulsatility index (TPI): $TPI = (v_{mix} \max - v_{mix} \min) / (v_{mix} \text{ mean})$,
- the tissue resistance index (TRI): $TRI = (v_{mix} \max - v_{mix} \min) / (v_{mix} \max)$.

Each of these parameters was calculated using the data from all imaged vessels in color Doppler mode, coded as red and blue to reflect the direction and velocity of blood particle movement. The results representing the sum of the “red” and “blue” values were referred to as the “mix” value for each parameter (v_{mix} , I_{mix} , A_{mix} , TPI_{mix} , and TRI_{mix}). In addition to these methods for quantifying per-

fusion, visual impressions of the vasculature were obtained by using the “perfusion relief”, which was also determined by the software and depicts the local distribution of perfusion intensity, much like a map encoding different heights in a landscape using different colors.

The ROI was outlined as a parallelogram in the sonographic image. It was in the renal parenchyma in the area between the outer border of the medullary pyramids and the kidney surface (Figure 1), thus including the interlobular arteries in the investigation and excluding the arcuate and interlobar arteries. The ROI contained vessels running in a symmetrical distribution pattern to the transducer, branching off from the central interlobar artery. This artery was always central and ran straight towards the transducer. The parallelogram was then placed to include a complete vascular segment fed by this interlobar artery. Digital videos (DICOM format) containing 25–90 images and at least one full heart cycle were recorded. The velocity range of the color depiction was adjusted to minimize aliasing in the ROI.

Videos with movement artefacts were either excluded from perfusion quantification or the relevant video frames without artefacts were manually selected. A breath hold technique was applied when cooperation with children was good. In other patients, the videos were recorded when the patients were calm and only the frames without artefacts were chosen for the analysis.

Statistical analysis

Statistical analysis was performed using IBM SPSS software, version 21.0. The study groups and control group were compared. Descriptive statistics for continuous data were calculated. The Kolmogorov-Smirnov test was used to define the data distribution. One-way analysis of variance (ANOVA) was used to compare groups for variables with a normal distribution, and the Kruskal-Wallis test was used for variables with a non-normal distribution. Post-hoc multiple comparisons were conducted using the least significant difference test (LSD test). Values of $p < 0.05$ were considered statistically significant.

Results

Data from all patients were considered technically adequate for the DTPM performed using the PixelFlux software (Chameleon-Software, Germany). Statistical analysis showed no statistically significant differences between the groups in terms of age, sex, or BMI.

Cortical parenchymal perfusion in children suffering from UTIs and VUR was significantly reduced when compared to the control group of

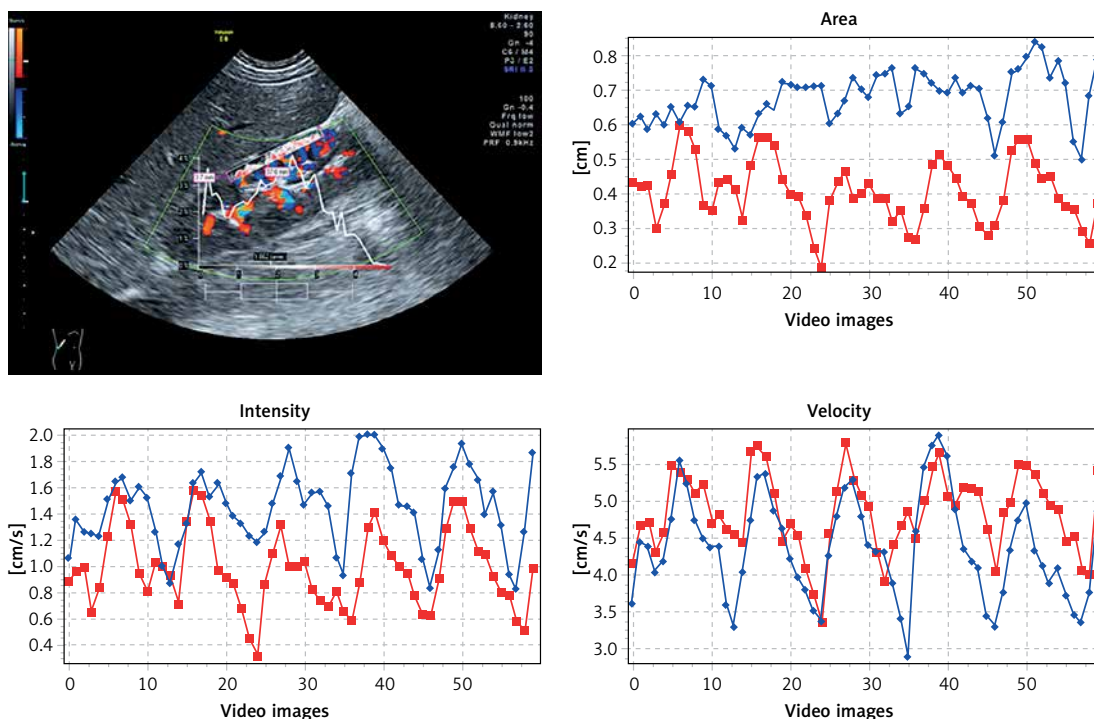


Figure 1. Illustration of signal quantification in a kidney with PixelFlux. Top left – color Doppler – the first frame of a video sequence with a parallelogram placed between the outer border of the medullary pyramids and the renal surface. Three diagrams showing changes in relevant perfusion parameters: red lines refer to red color Doppler pixels, blue lines to blue pixels. Top right – changes in perfused area; bottom left – changes in mean flow intensity; bottom right – changes in mean flow velocity

healthy children (Table I). Statistically significant differences were found between the control group and study group 1 (with UTIs and VUR) in all measured perfusion parameters (i.e. mean velocity (v_{mix}), mean perfused area (A_{mix}), perfusion intensity, I_{mix} , TPI , and TRI). There was no significant difference between the control group and VUR grade II when the VUR grade was taken into account. In contrast, there were significant differences between the control group and VUR grades III and IV (Figures 2–4) in almost all analyzed parameters, with VUR grade IV showing greater impairment of the perfusion parameters than VUR grade III (Table II). The exception was TRI_{mix} , which did not differ significantly between VUR grade III and the

control group. Moreover, most perfusion parameters (i.e. all except v_{mix}) in the group of patients with VUR grade II were slightly higher than those of the control group, but the differences were not statistically significant. There were no significant differences in parenchymal perfusion between study group 2 (children suffering solely from recurrent UTIs) and the control group in any of the perfusion parameters (Table I).

Discussion

Parenchymal perfusion is a crucial prerequisite for normal renal function [7]. In children with VUR perfusion parameters slowly deteriorate together with the development of renal scarring. Early

Table I. Mean values of perfusion parameters in study groups 1 and 2 and the control group. Cortical parenchymal perfusion of children from study group 1 (suffering from urinary tract infections (UTIs) and vesicoureteral reflux (VUR)) was significantly reduced relative to the control group of healthy children in all measured parameters. No significant differences in parenchymal perfusion were found between study group 2 (children suffering solely from recurrent UTIs) and the control group for any of the measured perfusion parameters

Variable	v_{mix}	A_{mix}	I_{mix}	TRI_{mix}	TPI_{mix}
Study group 1 (UTIs + VUR)	3.5641*	0.2705*	0.5632*	0.6488*	1.1929*
Study group 2 (UTIs)	4.0704	0.3469	0.7326	0.5425	0.8222
Control group	4.1955	0.3360	0.7088	0.5235	0.7970

*Statistical difference vs. control group at $p < 0.05$.

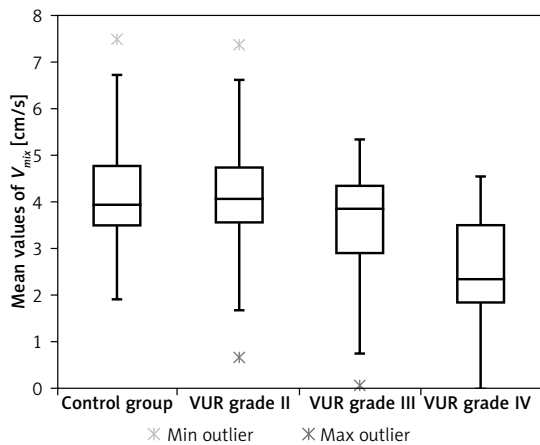


Figure 2. Mean values of v_{mix} in study group 1 (UTIs and VUR) according to VUR grade/control group. No significant difference between control group and VUR grade II, significant differences between control group and VUR grades III and IV

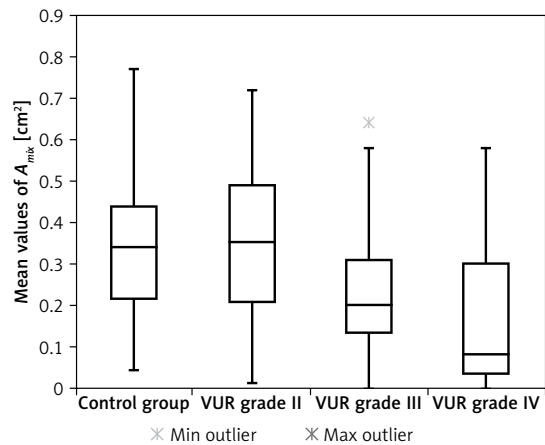


Figure 3. Mean values of A_{mix} in study group 1 (UTIs and VUR) according to VUR grade/control group. No significant difference between control group and VUR grade II, significant differences between control group and VUR grades III and IV

stages of renal parenchymal deterioration, when introducing more aggressive treatment could lead to better therapeutic results, are however difficult to diagnose with routinely used methods such as color/spectral Doppler ultrasound or scintigraphy. To prevent a silent decrease of renal function, novel methods are necessary to monitor stealthy changes in renal parenchyma [7]. An ideal method in pediatrics should be harmless, radiation free, non-invasive, widely available and inexpensive. The technique used in the current study – color Doppler sonographic dynamic tissue perfusion measurement (DTPM) – fulfils all the criteria.

Dynamic tissue perfusion measurement (DTPM) vs. Doppler techniques

In comparison to standard techniques used for the description of renal perfusion such as color Doppler and measurement of flow velocity indices in intrarenal arteries (resistance index (RI) and pulsatility index (PI)) the new technique offers detailed flow information at each single point of streaming blood. This novel method enables this information to be extracted by calculation of flow

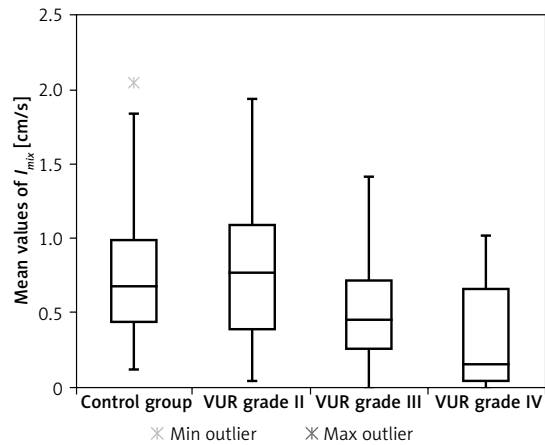


Figure 4. Mean values of I_{mix} in study group 1 (UTIs and VUR) according to VUR grade/control group. No significant difference between control group and VUR grade II, significant differences between control group and VUR grades III and IV

velocities at any location in tissues simultaneously at any time point of a video sequence. Quality of tissue perfusion is thus perceivable in a much more detailed manner. Moreover, TPI enables

Table II. Mean values of perfusion parameters in study group 1 (suffering from urinary tract infections (UTIs) and vesicoureteral reflux (VUR)) according to VUR grade/control group. There was no significant difference in renal parenchymal perfusion between the control group and VUR grade II, whereas there were significant differences between the control group and VUR grades III and IV in almost all measured perfusion parameters

Variable	v_{mix}	A_{mix}	I_{mix}	TRI_{mix}	TPI_{mix}
Control group	4.1955	0.3360	0.7088	0.5235	0.7970
VUR grade II	4.1705	0.3585	0.7908	0.5487	1.0921
VUR grade III	3.5580*	0.2432*	0.4824*	0.5939	1.1122*
VUR grade IV	2.4114*	0.1667*	0.3052*	0.9381*	1.4252*

*Significant difference vs. control group at $p < 0.05$.

measurements in many cortical vessels simultaneously [13]. The novel parameters TRI and TPI have the capacity to describe the state of the renal vascular tree in a formerly unmatched subtlety [13].

Another great advantage of the DTPM method and the great novelty is the fact that recording a short digital color Doppler video containing only one full heart cycle is sufficient to perform all the measurements of all five parameters of the perfusion, e.g. velocity (v_{mix}), intensity (I_{mix}), area (A_{mix}), tissue pulsatility index (TPI_{mix}) and tissue resistance index (TRI_{mix}), at the same time. In contrast, performing standard spectral Doppler measurement of flow velocity indices in intrarenal arteries may be extremely difficult or even impossible, as well as time-consuming in infants and younger children, who are the majority of patients suffering from VUR. The new method enables reliable measurements of the perfusion parameters to be made during post-processing, at any time after the examination, when the presence of the patient and good cooperation with the patient are not crucial conditions.

Renal perfusion parameters in children suffering from VUR – current study

The results of the current study revealed a significant reduction in cortical parenchymal perfusion in children suffering from UTIs and VUR when compared to the control group of healthy children for all measured perfusion parameters. Moreover, when the grade of VUR was taken into account, statistically significant differences were found between the control group and VUR grades III and IV for almost all analyzed parameters. In contrast, VUR grade II did not differ significantly from the control group. Likewise, there were no significant differences in parenchymal perfusion between children suffering solely from recurrent UTIs and the control group for any of the measured perfusion parameters. The results showed that significant impairment of renal parenchymal perfusion occurs between VUR grades II and III. This is a very important message for the management of VUR in children, proving that higher grades of VUR, starting from VUR grade III, should be treated more aggressively in order to prevent a decrease of the renal cortical perfusion parameters and in consequence deterioration of the renal function. The slight increase in most perfusion parameters in the group of patients with VUR grade II compared to the control group, although not statistically significant, might suggest that early stages of VUR provoke a kidney response and may be a potential mechanism of auto-defense, since a relatively large percentage of lower degrees of VUR, particularly at an early age, may spontaneously resolve with time [14, 15].

Renal perfusion in children suffering from VUR – literature review

The review of the literature shows that the renal perfusion parameters in children with UTIs and/or VUR have not been previously extensively described. The results obtained in our study are similar to those published by Frauscher *et al.* and Radmayr *et al.*, where the authors measuring renal resistive index (RI) at the level of the interlobar/arcuate arteries using color Doppler demonstrated that children with VUR grade I–III showed RI values less than the normal physiological upper limit, whereas patients with VUR grade IV–V demonstrated a significant increase of RI value [16, 17]. Apart from these single publications found in the literature, no other reports describing renal parenchymal perfusion measurements in children with UTIs and/or VUR seem to have been published. This is probably because there were no *in vivo* measures of renal perfusion, which can be easily performed in children, non-invasively or without exposure to exogenous compounds or ionizing radiation [18].

Renal perfusion measurement – available techniques

Renal perfusion measurement, however, is a crucial part of measuring kidney function since it is one of the main determinants of glomerular filtration rate and tissue oxygenation [19]. The development of magnetic resonance imaging (MRI) has permitted more widespread use of arterial spin labeling perfusion measurements in clinical practice [18]. However, MRI carries the risk associated with the necessary general anesthesia in smaller children, and remains a relatively expensive method with limited availability. Measurement of renal perfusion using computed tomography (CT) is also currently possible [20], but the risks associated with its use (e.g. ionizing radiation, need for general anesthesia, and the use of iodine contrast agents) are too high for it to be recognized as a good follow-up tool for the pediatric population. Standard ultrasonography enables perfusion measurements, but only in the main feeding arteries [10]. Contrast enhanced ultrasound (CEUS) is another technique used for the assessment of renal parenchymal vascularity [21]. However, CEUS can only be performed off-license in children currently [22], is expensive, and requires intravenous application, thus making this technique too invasive for screening or routine follow-up. Therefore, the assessment of renal parenchymal perfusion using the DTPM technique may become an important diagnostic tool, enabling the identification of children with deteriorating renal parenchymal perfusion. This would assist in de-

termining whether to use a more aggressive treatment before the development of renal scarring.

The authors realize that the study has some limitations. A single-center design may be one of the restrictions of the study. Another is the fact that some of the examinations were performed during breathing and that the region of interest was not covering all the renal parenchyma, but only a part of it. While this resulted from the possibilities of the software, we believe that the ROI chosen for analysis was representative for all renal parenchyma. Therefore the results may be translated for total renal parenchymal perfusion, particularly since children included in the study group did not show renal scarring, which could potentially cause a bias.

In conclusion, our study shows that color Doppler sonographic dynamic tissue perfusion measurement (DTPM) using PixelFlux (Chameleon-Software, Germany) software is a reliable technique for evaluating renal parenchymal perfusion in children with recurrent UTIs and VUR. The results prove that the perfusion parameters are significantly reduced in children suffering from VUR grades III and IV, whereas they do not differ significantly in VUR grade II and in children with UTIs without co-existing VUR from the control group. These results could form a starting point for creating a new therapeutic algorithm incorporating renal parenchymal perfusion as an important diagnostic and prognostic factor, thus enabling alterations in treatment before renal function deteriorates and irreversible renal scarring occurs. These results need to be confirmed by further studies on larger populations, possibly in a multi-center design.

Acknowledgments

This study was funded by a research grant from the National Science Center, no. NN403456137, Poland.

Conflict of interest

The authors declare no conflict of interest.

References

1. Galloy MA, Mandy D, Pecastaings M, Mainard-Simard L, Claudon M. Sonocystography: a new method for the diagnosis and follow-up of vesico-ureteric reflux in children. *J Radiol* 2003; 84: 2055-61.
2. Routh JC, Bogaert GA, Kaefer M, et al. Vesicoureteral reflux: current trends in diagnosis, screening, and treatment. *Eur Urol* 2012; 61: 773-82.
3. Snodgrass WT, Shah A, Yang M, et al. Prevalence and risk factors for renal scars in children with febrile UTI and/or VUR: a cross-sectional observational study of 565 consecutive patients. *J Pediatr Urol* 2013; 9: 856-63.
4. Rodriguez LV, Spielman D, Herfkens RJ, Shortliffe LD. Magnetic resonance imaging for the evaluation of hydronephrosis, reflux and renal scarring in children. *J Urol* 2001; 166: 1023-7.
5. Kocyigit A, Yuksel S, Bayram R, Yilmaz I, Karabulut N. Efficacy of magnetic resonance urography in detecting renal scars in children with vesicoureteral reflux. *Pediatr Nephrol* 2014; 29: 1215-20.
6. Wieczorek AP, Wozniak MM, Stankiewicz A, et al. Quantitative assessment of urethral vascularity in nulliparous females using high-frequency endovaginal ultrasonography. *World J Urol* 2011; 29: 625-32.
7. Scholbach T, Girelli E, Scholbach J. Dynamic tissue perfusion measurement: a novel tool in follow-up of renal transplants. *Transplantation* 2005; 79: 1711-6.
8. Scholbach T, Scholbach J, Krombach GA, Gagel B, Maneschi P, Di Martino E. New method of dynamic color doppler signal quantification in metastatic lymph nodes compared to direct polarographic measurements of tissue oxygenation. *Int J Cancer* 2005; 114: 957-62.
9. Scholbach T, Herrero I, Scholbach J. Dynamic color Doppler sonography of intestinal wall in patients with Crohn disease compared with healthy subjects. *J Pediatr Gastroenterol Nutr* 2004; 39: 524-8.
10. Scholbach T, Dimos I, Scholbach J. A new method of color Doppler perfusion measurement via dynamic sonographic signal quantification in renal parenchyma. *Nephron Physiol* 2004; 96: 99-104.
11. Scholbach TM, Vogel C, Bergner N. Color Doppler sonographic dynamic tissue perfusion measurement demonstrates significantly reduced cortical perfusion in children with diabetes mellitus type 1 without microalbuminuria and apparently healthy kidneys. *Ultraschall Med* 2014; 35: 445-50.
12. Woźniak MM, Wieczorek AP, Zajączkowska MM, Borzęcka H, Nachulewicz P. 2D/3D/4D contrast-enhanced voiding urosonography in the diagnosis and monitoring of treatment of vesicoureteral reflux in children – can it replace voiding cystourethrography? *J Ultrason* 2013; 13: 394-407.
13. Scholbach T, Girelli E, Scholbach J. Tissue pulsatility index: a new parameter to evaluate renal transplant perfusion. *Transplantation* 2006; 81: 751-5.
14. Wildbrett P, Schwebs M, Abel JR, Lode H, Barthlen W. Spontaneous vesicoureteral reflux resolution in children: a ten-year single-centre experience. *Afr J Paediatr Surg* 2013; 10: 9-12.
15. Knudson MJ, Austin JC, McMillan ZM, Hawtrey CE, Cooper CS. Predictive factors of early spontaneous resolution in children with primary vesicoureteral reflux. *J Urol* 2007; 178: 1684-8.
16. Frauscher F, Radmayr C, Klauser A, et al. Assessment of renal resistance index in children with vesico-ureteral reflux. *Ultraschall Med* 1999; 20: 93-7.
17. Radmayr C, Klauser A, Maneschg C, Bartsch G, Frauscher F. Importance of the renal resistive index in children suffering from vesicoureteral reflux. *Eur Urol* 1999; 36: 75-9.
18. Gillis KA, McComb C, Foster JE, et al. Inter-study reproducibility of arterial spin labelling magnetic resonance imaging for measurement of renal perfusion in healthy volunteers at 3 Tesla. *BMC Nephrol* 2014; 15: 23.
19. Levey AS, Stevens LA, Schmid CH, et al. A new equation to estimate glomerular filtration rate. *Ann Intern Med* 2009; 150: 604-12.
20. Zhao H, Gong J, Wang Y, Zhang Z, Qin P. Renal hemodynamic changes with aging: a preliminary study using CT perfusion in the healthy elderly. *Clin Imaging* 2010; 34: 247-50.

21. Farhat W, Traubici J, Sherman C, Williams T, Babyn P, McLorie G. Reliability of contrast enhanced sonography with harmonic imaging for detecting early renal scarring in experimental pyelonephritis in a porcine model: preliminary results. *J Urol* 2002; 168: 1114-7.
22. Claudon M, Dietrich CF, Choi BI, et al. Guidelines and good clinical practice recommendations for Contrast Enhanced Ultrasound (CEUS) in the liver – update 2012: A WFUMB-EFSUMB initiative in cooperation with representatives of AFSUMB, AIUM, ASUM, FLAUS and ICUS. *Ultrasound Med Biol* 2013; 39: 187-210.